



National
Comprehensive
Cancer
Network®

NCCN Clinical Practice Guidelines in Oncology (NCCN Guidelines®)

Penile Cancer

Version 1.2016

NCCN.org

Continue



National
Comprehensive
Cancer
Network®

NCCN Guidelines Version 1.2016 Panel Members

Penile Cancer

[NCCN Guidelines Index](#)
[Penile Cancer TOC](#)
[Discussion](#)

*Peter E. Clark, MD [⊞] Chair
Vanderbilt-Ingram Cancer Center

*Philippe E. Spiess, MD, MS [⊞] Vice chair
Moffitt Cancer Center

Neeraj Agarwal, MD [‡] †
Huntsman Cancer Institute
at the University of Utah

Stephen A. Boorjian, MD [⊞]
Mayo Clinic Cancer Center

Mark K. Buyyounouski, MD, MS [§]
Stanford Cancer Institute

Jason A. Efstathiou, MD, DPhil [§]
Massachusetts General Hospital Cancer Center

Thomas W. Flaig, MD †
University of Colorado Cancer Center

Terence Friedlander, MD †
UCSF Helen Diller Family
Comprehensive Cancer Center

Richard E. Greenberg, MD [⊞]
Fox Chase Cancer Center

Khurshid A. Guru, MD [⊞]
Roswell Park Cancer Institute

Noah Hahn, MD †
The Sidney Kimmel Comprehensive
Cancer Center at Johns Hopkins

Harry W. Herr, MD [⊞]
Memorial Sloan Kettering Cancer Center

Christopher Hoimes, MD †
Case Comprehensive Cancer Center/
University Hospitals Seidman Cancer Center and
Cleveland Clinic Taussig Cancer Institute

Brant A. Inman, MD, MSc [⊞]
Duke Cancer Institute

A. Karim Kader, MD, PhD [⊞]
UC San Diego Moores Cancer Center

Adam S. Kibel, MD [⊞]
Dana-Farber/Brigham and
Women's Cancer Center

Timothy M. Kuzel, MD [‡]
Robert H. Lurie Comprehensive Cancer
Center of Northwestern University

Subodh M. Lele, MD [≠]
Fred & Pamela Buffett Cancer Center

Jeff Michalski, MD, MBA [§]
Siteman Cancer Center at Barnes-
Jewish Hospital and Washington
University School of Medicine

Jeffrey S. Montgomery, MD, MHSA [⊞]
University of Michigan
Comprehensive Cancer Center

Lance C. Pagliaro, MD †
Mayo Clinic Cancer Center

Sumanta K. Pal, MD †
City of Hope Comprehensive Cancer Center

Anthony Patterson, MD [⊞]
St. Jude Children's Research Hospital/
University of Tennessee Health Science Center

Daniel Petrylak, MD †
Yale Cancer Center/Smilow Cancer Hospital

Elizabeth R. Plimack, MD, MS †
Fox Chase Cancer Center

Kamal S. Pohar, MD [⊞]
The Ohio State University Comprehensive
Cancer Center - James Cancer Hospital
and Solove Research Institute

Michael P. Porter, MD, MS [⊞]
Fred Hutchinson Cancer Research Center/
Seattle Cancer Care Alliance

Wade J. Sexton, MD [⊞]
Moffitt Cancer Center

Arlene O. Siefker-Radtke, MD †
The University of Texas
MD Anderson Cancer Center

Guru Sonpavde, MD †
University of Alabama at Birmingham
Comprehensive Cancer Center

Jonathan Tward, MD, PhD [§]
Huntsman Cancer Institute
at the University of Utah

Geoffrey Wile, MD [⊞]
Vanderbilt-Ingram Cancer Center

NCCN
Mary Dwyer, MS
Courtney Smith, PhD

Continue

[⊞] Urology	[⊞] Diagnostic radiology
[†] Medical oncology	[≠] Pathology
[‡] Hematology/Hematology oncology	* Discussion writing committee member
[§] Radiotherapy/Radiation oncology	

[NCCN Guidelines Panel Disclosures](#)





[NCCN Penile Cancer Panel Members](#) [Summary of the Guidelines Updates](#)

[Primary Evaluation, Clinical Diagnosis \(PN-1\)](#)

[Primary Treatment Tis, Ta \(PN-1\)](#)

[Primary Treatment T1, T2 or Greater \(PN-2\)](#)

[Management of Non-Palpable Inguinal Lymph Nodes \(PN-3\)](#)

[Management of Palpable Non-Bulky Inguinal Lymph Nodes \(PN-4\)](#)

[Management of Palpable Bulky Inguinal Lymph Nodes \(PN-5\)](#)

[Management of Enlarged Pelvic Lymph Nodes \(PN-6\)](#)

[Surveillance Schedule \(PN-7\)](#)

[Management of Recurrent Disease \(PN-8\)](#)

[Management of Metastatic Disease \(PN-9\)](#)

[Principles of Surgery \(PN-A\)](#)

[Principles of Radiotherapy \(PN-B\)](#)

[Principles of Chemotherapy \(PN-C\)](#)

Clinical Trials: NCCN believes that the best management for any cancer patient is in a clinical trial. Participation in clinical trials is especially encouraged.

To find clinical trials online at NCCN Member Institutions, [click here: nccn.org/clinical_trials/physician.html](#).

NCCN Categories of Evidence and Consensus: All recommendations are category 2A unless otherwise specified.

See [NCCN Categories of Evidence and Consensus](#).

[Staging \(ST-1\)](#)

The NCCN Guidelines® are a statement of evidence and consensus of the authors regarding their views of currently accepted approaches to treatment. Any clinician seeking to apply or consult the NCCN Guidelines is expected to use independent medical judgment in the context of individual clinical circumstances to determine any patient's care or treatment. The National Comprehensive Cancer Network® (NCCN®) makes no representations or warranties of any kind regarding their content, use or application and disclaims any responsibility for their application or use in any way. The NCCN Guidelines are copyrighted by National Comprehensive Cancer Network®. All rights reserved. The NCCN Guidelines and the illustrations herein may not be reproduced in any form without the express written permission of NCCN. ©2016.



NCCN Guidelines Version 1.2016 Updates

Penile Cancer

Summary of the changes in the 1.2016 version of the Guidelines for Penile Cancer from the 3.2015 version include:

General

- “Radiotherapy with concurrent chemotherapy” was replaced with “chemoradiotherapy” throughout.

PN-2

- T2 or greater, “T2 tumors only” qualifier was removed for the primary treatment options of radiotherapy and chemoradiotherapy.

PN-3

- Imaging was added after intermediate and high risk as, “Abdominal/pelvic CT or MRI and Chest imaging (x-ray, or CT).”
- Treatment for “Dynamic sentinel node biopsy”, the category was changed from a category 2B to a category 2A. Also for PN-A.
- Footnote “n” was added, “Consider prophylactic EBRT to inguinal lymph nodes in patients who are not surgical candidates or who decline surgical management.”

PN-4

- Imaging was added for palpable ILN as “Abdominal/pelvic CT or MRI and Chest imaging (x-ray, or CT).”
- Management of palpable inguinal lymph nodes, the risk stratification groups were clarified as,
 - ▶ Unilateral mobile lymph node(s) <4 cm
 - ▶ Unilateral lymph nodes ≥4 cm (fixed or mobile) or Bilateral lymph node(s) (fixed or mobile)
 - ▶ Enlarged pelvic lymph nodes
- For non-bulky, unilateral mobile lymph node(s) <4 cm, after treatment with ILND, options for pN1 and pN2-3 disease were added.
- Footnotes
 - ▶ Footnote “o” was added, “Consider PET-CT scan.”
 - ▶ Footnote “p” was added, “If M1 disease identified, see Management of Metastatic Disease (PN-9).”
 - ▶ Footnote “q” was added, “The size threshold of 4 cm represents the largest diameter of contiguous inguinal lymph node(s) tissue as measured on either physical examination and/or axial imaging (CT or MR) and suspected of harboring metastatic disease.” Also for PN-5.

PN-5

- For bulky, unilateral ≥4 cm (fixed or mobile) or Bilateral (fixed or mobile), the lymph node status was clarified as,
 - ▶ Unilateral mobile ≥4 cm and
 - ▶ Unilateral fixed lymph nodes ≥4 cm or bilateral lymph node(s) (fixed or mobile)
- For unilateral mobile ≥4 cm, after treatment for a positive node, if ≥2 nodes positive or extranodal extension, “Adjuvant chemotherapy (if not already given)” was added.
- Footnote “u” was added, “Data suggest that in the setting of ≥4 positive inguinal lymph nodes, bilateral PLND should be performed. Zargar-Shoshtari K, Djajadiningrat R, Sharma P, et al. Establishing Criteria for Bilateral Pelvic Lymph Node Dissection in the Management of Penile Cancer: Lessons Learned from an International Multicenter Collaboration. J Urol 2015;194:696-701.”

PN-6

- Pelvic lymph nodes enlarged, “needle biopsy” was added and the option for negative nodes was added.

PN-8

- Local recurrence in inguinal region, the options were changed from “Consider systemic chemotherapy and/or Consider external beam radiation therapy (EBRT) and/or Consider surgical resection” to “Chemotherapy followed by surgical resection or Chemoradiotherapy or Chemotherapy alone.”
- Footnote “aa” was added, “Baumgarten AS, Alhammali E, Hakky TS, et al. Salvage surgical resection for isolated locally recurrent inguinal lymph node metastasis of penile cancer: international study collaboration. J Urol 2014;192:760-764.”

Principles of Radiotherapy

PN-B

- Primary radiation therapy, if tumor <4 cm, “Consider prophylactic EBRT to inguinal lymph nodes in patients who are not surgical candidates or who decline surgical management” was added to EBRT.

Principles of Chemotherapy

PN-C 2 of 2

- TIP, “Repeat every 21 days” was clarified as, “Repeat every 3 to 4 weeks.”
- Reference #3 was updated, “Hakenberg OW, Compérat EM, Minhas S, Necchi A, Protzel C, Watkin N; European Association of Urology. EAU guidelines on penile cancer: 2014 update. Eur Urol 2015;67:142-150.”
- Reference #6 was updated, “Wang J, Pettaway CA, Pagliaro LC. Treatment for metastatic penile cancer after first-line chemotherapy failure: analysis of response and survival outcomes. Urology 2015;85:1104-1110.”

Note: All recommendations are category 2A unless otherwise indicated.

Clinical Trials: NCCN believes that the best management of any cancer patient is in a clinical trial. Participation in clinical trials is especially encouraged.



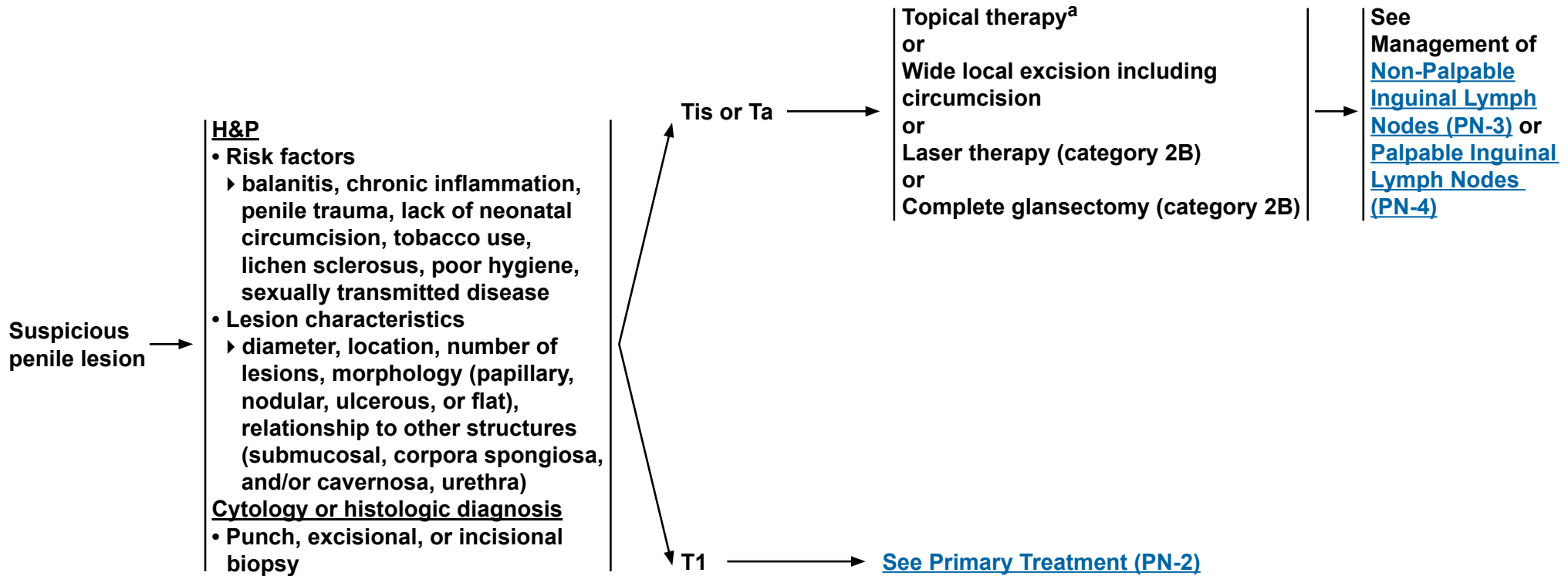
NCCN Guidelines Version 1.2016

Penile Cancer

PRIMARY EVALUATION

CLINICAL DIAGNOSIS

PRIMARY TREATMENT



If recurrent disease, [see PN-8](#) or if metastatic disease, [see PN-9](#)


^aTopical therapy may include topical imiquimod (5%) or 5-fluorouracil (5-FU) cream.

Note: All recommendations are category 2A unless otherwise indicated.
Clinical Trials: NCCN believes that the best management of any cancer patient is in a clinical trial. Participation in clinical trials is especially encouraged.



NCCN Guidelines Version 1.2016

Penile Cancer



^bSee [Principles of Surgery \(PN-A\)](#).

^cMoh's surgery is an option.

^dComplete excision of the skin with a wide negative margin with skin grafting is needed. STSG = split-thickness skin graft; FTSG= full-thickness skin graft.

^eSee [Principles of Radiotherapy \(PN-B\)](#).

^fRecommend intraoperative frozen sections to achieve negative margins.

^gAppropriate with proven negative margins for tumors involving the glans only.

^hWhen it is necessary to dissect into the corpora cavernosum to achieve a negative margin, a partial or total penectomy is performed.

ⁱSee [Principles of Chemotherapy \(PN-C\)](#).

Note: All recommendations are category 2A unless otherwise indicated.

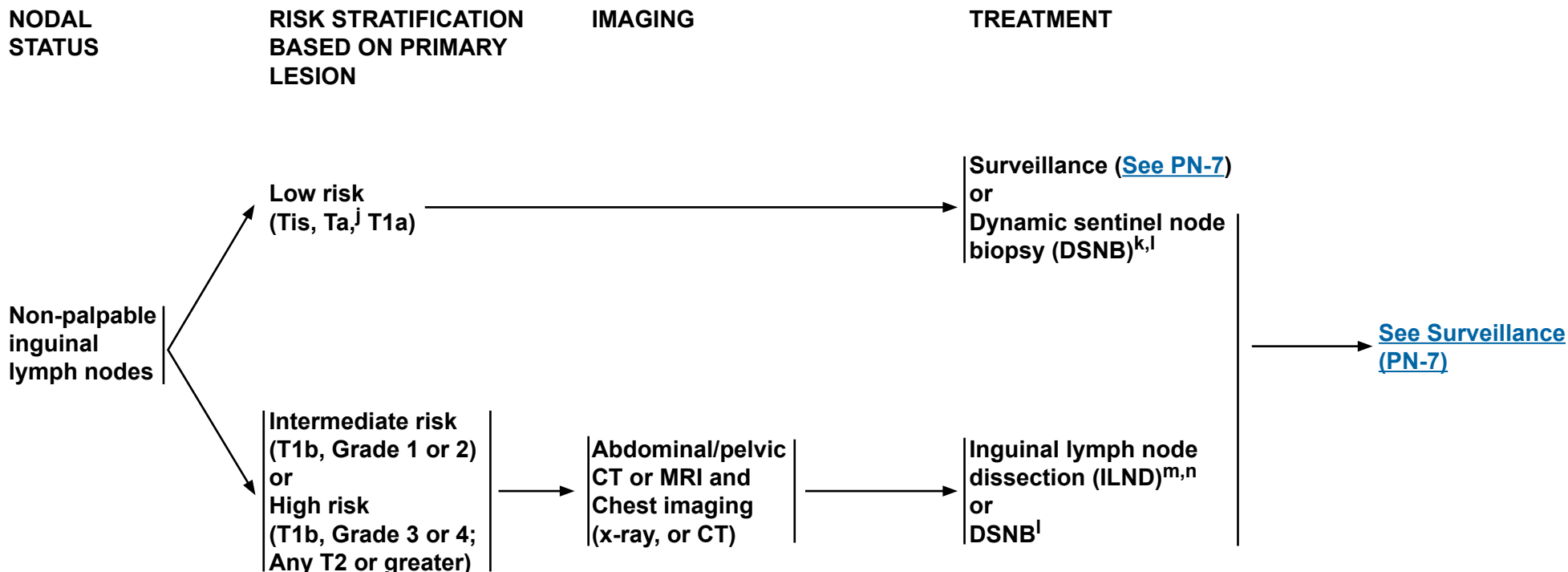
Clinical Trials: NCCN believes that the best management of any cancer patient is in a clinical trial. Participation in clinical trials is especially encouraged.



NCCN Guidelines Version 1.2016

Penile Cancer

MANAGEMENT OF NON-PALPABLE INGUINAL LYMPH NODES



^jTa verrucous carcinoma is by definition a well-differentiated tumor and would require surveillance alone of inguinal lymph nodes.

^kDSNB is recommended provided the treating physician has experience with this modality.

^lIf positive lymph nodes are found on DSNB, ILND is recommended.

^mA modified/superficial inguinal dissection with intraoperative frozen section is an acceptable alternative to stage the inguinal lymph nodes.

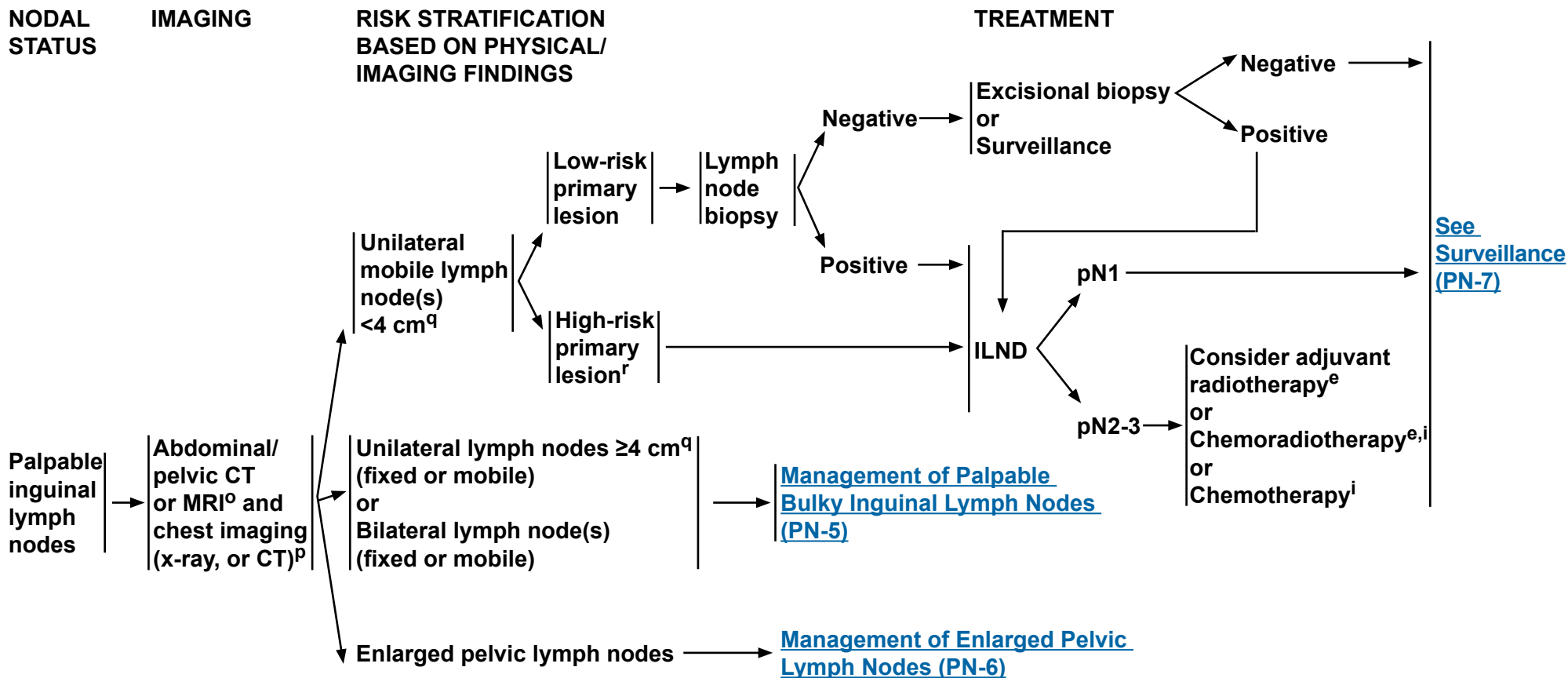
ⁿConsider prophylactic EBRT to inguinal lymph nodes in patients who are not surgical candidates or who decline surgical management.

Note: All recommendations are category 2A unless otherwise indicated.

Clinical Trials: NCCN believes that the best management of any cancer patient is in a clinical trial. Participation in clinical trials is especially encouraged.



MANAGEMENT OF PALPABLE NON-BULKY INGUINAL LYMPH NODES



^eSee Principles of Radiotherapy (PN-B)

ⁱSee Principles of Chemotherapy (PN-C).

^oConsider PET-CT scan.

^pIf M1 disease identified, see Management of Metastatic Disease (PN-9).

^qThe size threshold of 4 cm represents the largest diameter of contiguous inguinal lymph node(s) tissue as measured on either physical examination and/or axial imaging (CT or MR) and suspected of harboring metastatic disease.

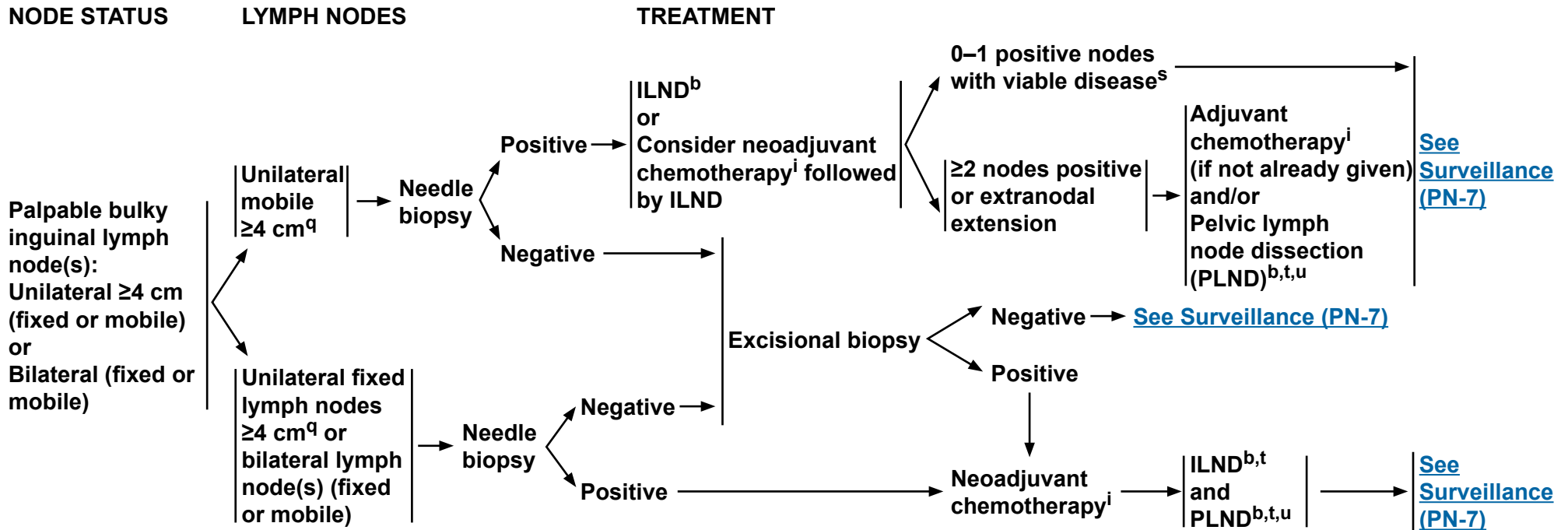
^rHigh-risk primary lesion: T1, high-grade, LVI, >50% poorly undifferentiated.

Note: All recommendations are category 2A unless otherwise indicated.

Clinical Trials: NCCN believes that the best management of any cancer patient is in a clinical trial. Participation in clinical trials is especially encouraged.



MANAGEMENT OF PALPABLE BULKY INGUINAL LYMPH NODES



^bSee Principles of Surgery (PN-A).

ⁱSee Principles of Chemotherapy (PN-C).

^qThe size threshold of 4 cm represents the largest diameter of contiguous inguinal lymph node(s) tissue as measured on either physical examination and/or axial imaging (CT or MR) and suspected of harboring metastatic disease.

^sFor viable disease post-chemotherapy, consider PLND.

^tConsider postoperative radiotherapy or chemoradiotherapy.

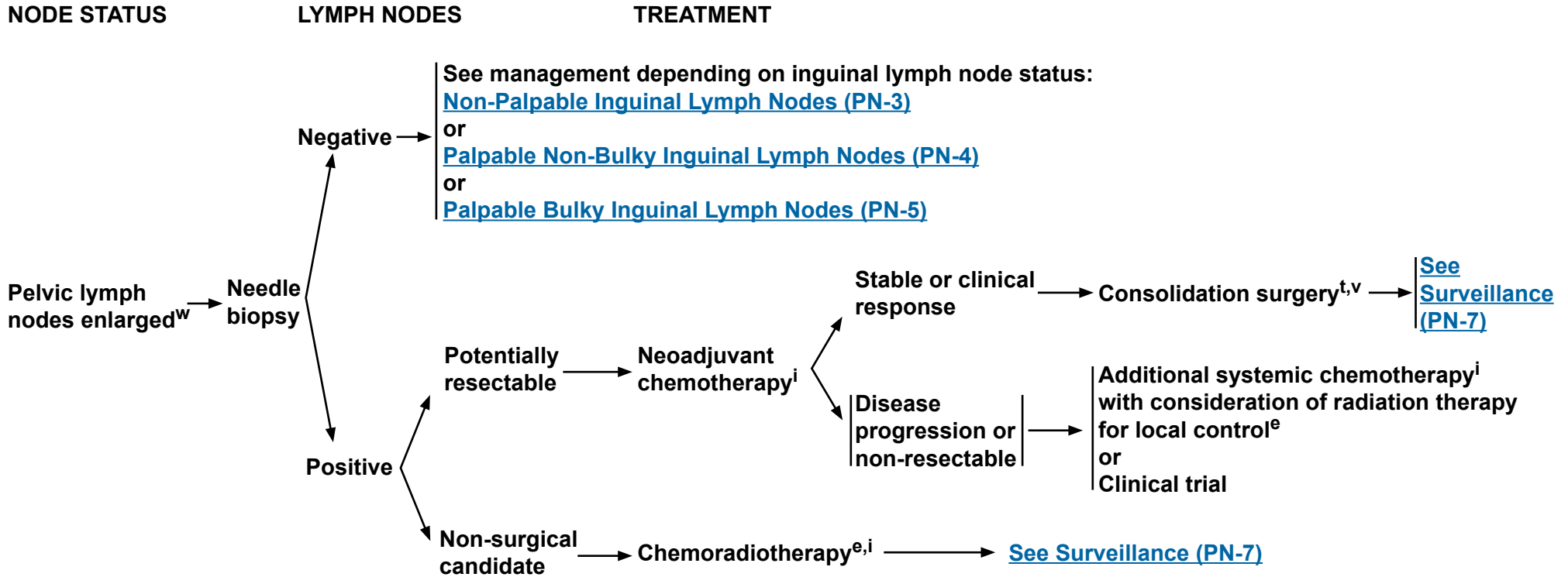
^uData suggest that in the setting of ≥4 positive inguinal lymph nodes, bilateral PLND should be performed. Zargar-Shoshtari K, Djajadiningrat R, Sharma P, et al. Establishing Criteria for Bilateral Pelvic Lymph Node Dissection in the Management of Penile Cancer: Lessons Learned from an International Multicenter Collaboration. J Urol 2015;194:696-701.

Note: All recommendations are category 2A unless otherwise indicated.

Clinical Trials: NCCN believes that the best management of any cancer patient is in a clinical trial. Participation in clinical trials is especially encouraged.



MANAGEMENT OF ENLARGED PELVIC LYMPH NODES



^eSee Principles of Radiotherapy (PN-B).

ⁱSee Principles of Chemotherapy (PN-C).

^tConsider postoperative radiotherapy or chemoradiotherapy.

^vConsolidation surgery consists of bilateral superficial and deep ILND and unilateral/bilateral PLND.

^wOn CT or MRI, not pathologic stage.

Note: All recommendations are category 2A unless otherwise indicated.

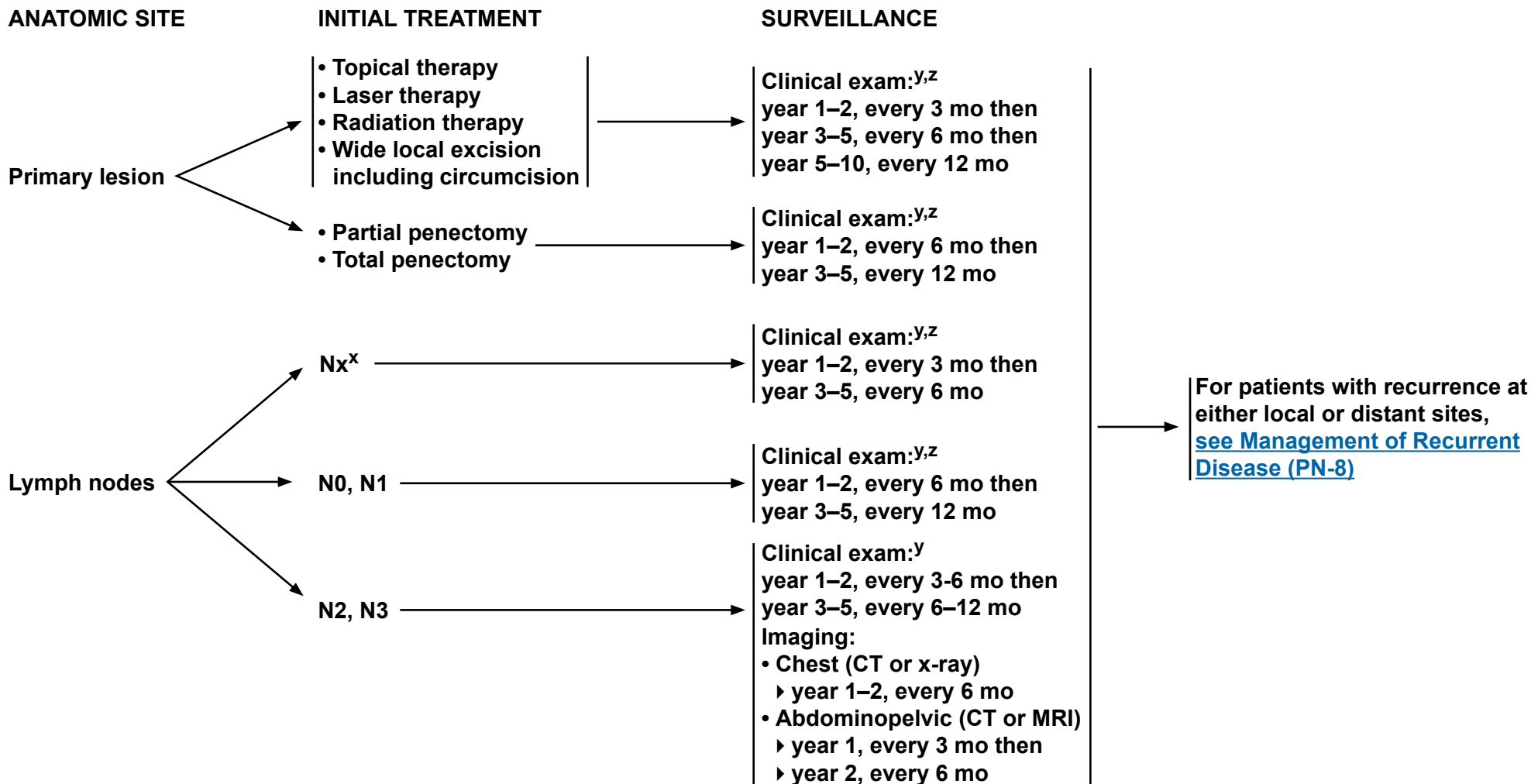
Clinical Trials: NCCN believes that the best management of any cancer patient is in a clinical trial. Participation in clinical trials is especially encouraged.



NCCN Guidelines Version 1.2016

Penile Cancer

SURVEILLANCE SCHEDULE



^XPatients on active surveillance of clinically negative nodes and at low risk for inguinal metastases.

^YClinical exam includes examination of the penis and inguinal region.

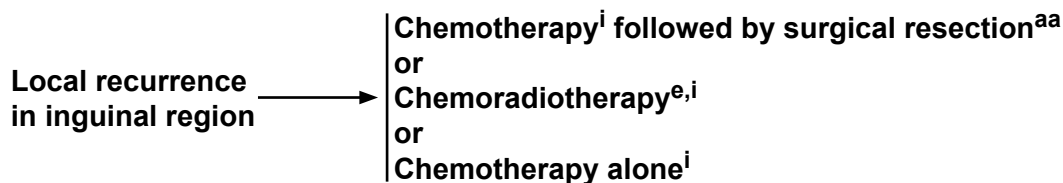
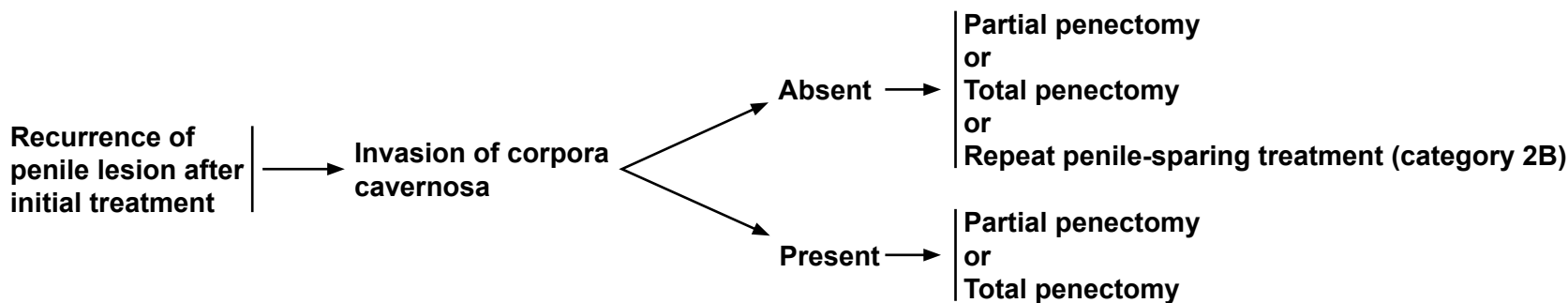
^ZIf an abnormal clinical exam, obese patient, or prior inguinal surgery, then ultrasound, CT, or MRI of the inguinal region can be considered.

Note: All recommendations are category 2A unless otherwise indicated.

Clinical Trials: NCCN believes that the best management of any cancer patient is in a clinical trial. Participation in clinical trials is especially encouraged.



MANAGEMENT OF RECURRENT DISEASE



^eSee [Principles of Radiotherapy \(PN-B\)](#).

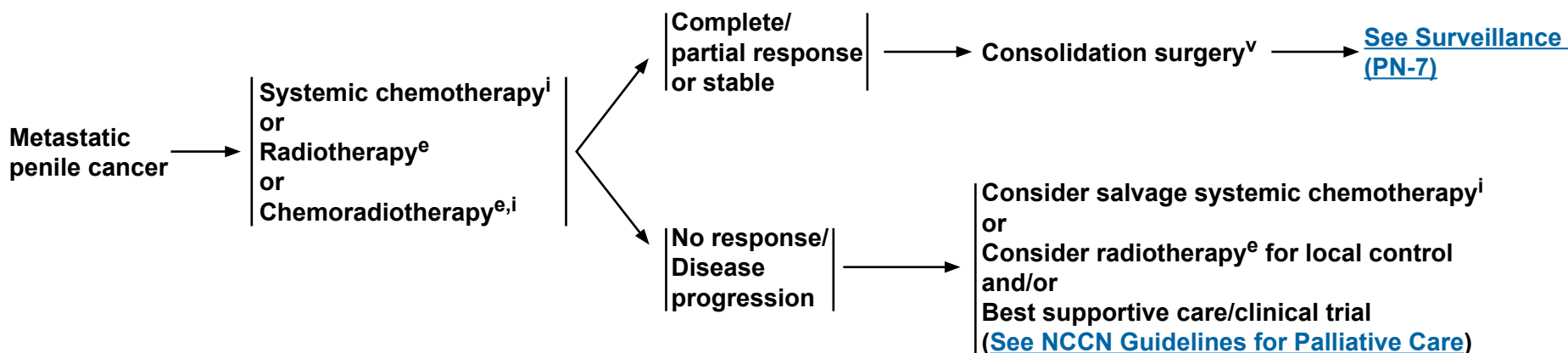
ⁱSee [Principles of Chemotherapy \(PN-C\)](#).

^{aa}Baumgarten AS, Alhammali E, Hakky TS, et al. Salvage surgical resection for isolated locally recurrent inguinal lymph node metastasis of penile cancer: international study collaboration. J Urol 2014;192:760-764.

Note: All recommendations are category 2A unless otherwise indicated.
Clinical Trials: NCCN believes that the best management of any cancer patient is in a clinical trial. Participation in clinical trials is especially encouraged.



MANAGEMENT OF METASTATIC DISEASE



^e[See Principles of Radiotherapy \(PN-B\).](#)

ⁱ[See Principles of Chemotherapy \(PN-C\).](#)

^vConsolidation surgery consists of bilateral superficial and deep ILND and possible bilateral PLND.

Note: All recommendations are category 2A unless otherwise indicated.

Clinical Trials: NCCN believes that the best management of any cancer patient is in a clinical trial. Participation in clinical trials is especially encouraged.

PRINCIPLES OF SURGERY¹

- **Tis, Ta penile cancer lesions may be amenable to conservative penile organ-sparing approaches, including: topical therapy, local excision, circumcision, laser therapy (category 2B), or glansectomy (category 2B).**
- **Partial penectomy should be considered the standard for high-grade primary penile tumors, provided a functional penile stump can be preserved and negative margins are obtained.**
- **Standard or modified ILND or DSNB is indicated in patients with penile cancer in the absence of palpable inguinal adenopathy if high-risk features for nodal metastasis are seen in the primary penile tumor:**
 - ▶ **Lymphovascular invasion**
 - ▶ **≥pT1G3 or ≥T2, any grade**
 - ▶ **>50% poorly differentiated**
- **PLND should be considered at the time of ILND in patients with ≥2 inguinal nodes (on frozen section) on the ipsilateral ILND site or in a delayed procedure in patients with extranodal extension.**

¹See Discussion for further details regarding ILND and PLND.

Note: All recommendations are category 2A unless otherwise indicated.

Clinical Trials: NCCN believes that the best management of any cancer patient is in a clinical trial. Participation in clinical trials is especially encouraged.



PRINCIPLES OF RADIOTHERAPY

Primary Radiation Therapy (category 2B) (Penile Preservation)

T1-2, N0

If tumor <4 cm

• Circumcision followed by either:

‣ Brachytherapy alone (preferred approach)^{1,2} (should be performed with interstitial implant);
or

‣ EBRT with or without concurrent chemotherapy:³ Total dose 65–70 Gy with conventional fractionation using appropriate bolus to primary penile lesion with 2-cm margins. Consider prophylactic EBRT to inguinal lymph nodes in patients who are not surgical candidates or who decline surgical management.

If tumor ≥4 cm

• Circumcision followed by either:

‣ EBRT with concurrent chemotherapy:³ 45–50.4 Gy to a portion of or whole penile shaft depending on bulk and extent of lesion plus pelvic/inguinal nodes, then boost primary lesion with 2-cm margins (total dose 60–70 Gy);
or

‣ Brachytherapy (in select cases and with careful post-treatment surveillance)

T3-4 or N+ (surgically unresectable)

• Circumcision followed by:

‣ EBRT with concurrent chemotherapy:³ 45–50.4 Gy to whole penile shaft, pelvic lymph nodes, and bilateral inguinal lymph nodes, then boost primary lesion with 2-cm margins and gross lymph nodes (total dose 60–70 Gy).

Postoperative Adjuvant Radiotherapy

• Inguinal Lymph Node Positive

‣ Inguinal and pelvic lymph node EBRT to 45–50.4 Gy (strongly consider concurrent chemotherapy³).

‣ Boost gross nodes and areas of extracapsular extension to a total dose of 60–70 Gy.

‣ Treat primary site of disease if positive margin.

• Primary Site Margin Positive

‣ Primary site of disease and surgical scar EBRT to 60–70 Gy (for close margin consider radiation treatment vs. observation).

‣ Treat bilateral inguinal lymph nodes and pelvic lymph nodes if no or inadequate lymph node dissection.

‣ Brachytherapy (in select cases)

¹Crook J, Ma C, Grimard L. World J Urol 2009;27:189-196.

²de Crevoisier R, Slimane K, Sanfilippo N, et al. Int J Radiat Oncol Biol Phys 2009;74:1150-1156.

³For potential radiosensitizing agents and combinations, see [Principles of Chemotherapy \(PN-C 2 of 2\)](#).

Note: All recommendations are category 2A unless otherwise indicated.

Clinical Trials: NCCN believes that the best management of any cancer patient is in a clinical trial. Participation in clinical trials is especially encouraged.



PRINCIPLES OF CHEMOTHERAPY

Neoadjuvant

- Neoadjuvant, cisplatin-based chemotherapy should be considered the standard (prior to ILND) in patients with ≥ 4 cm inguinal lymph nodes (fixed or mobile), if FNA is positive for metastatic penile cancer.¹
 - ▶ Patients with initially unresectable (T4) primary tumors may be downstaged by response to chemotherapy.
- A Tx, N2-3, M0 penile cancer can receive 4 courses of neoadjuvant paclitaxel, ifosfamide, and cisplatin (TIP).² Stable or responding disease should then undergo consolidative surgery with curative intent.
 - ▶ The phase II response rate was 50% in the neoadjuvant setting.
 - ▶ The estimated rate of long-term progression-free survival for intent to treat was 36.7%.
 - ▶ Improved progression-free and overall survival times were associated with objective response to chemotherapy.

Adjuvant

- There are no sufficient data to form conclusions about the use of adjuvant chemotherapy. By extrapolation from the neoadjuvant data, it is reasonable to give 4 courses of TIP in the adjuvant setting if it was not given preoperatively and the pathology shows high-risk features. ([See Management of Palpable Bulky Inguinal Lymph Nodes, PN-5](#)) Adjuvant EBRT or chemoradiotherapy can also be considered for patients with high-risk features, which include any of the following:
 - ▶ Pelvic lymph node metastases
 - ▶ Extranodal extension
 - ▶ Bilateral inguinal lymph nodes involved
 - ▶ 4 cm tumor in lymph nodes

Metastatic/Recurrent

- TIP is a reasonable first-line treatment for patients with metastatic penile cancer, including palliative treatment of patients with distant metastases.²
- 5-FU + cisplatin has been used historically for metastatic penile cancer and can be considered as an alternative to TIP.³ It appears to be effective for some patients, although the toxicities may be limiting and require dose reductions.⁴
- Bleomycin-containing regimens are associated with unacceptable toxicity⁵ and are no longer recommended.
- There are no randomized clinical trials due to the rarity of penile cancer in industrialized countries.

Second-line

- No standard second-line systemic therapy exists.
- A clinical trial is preferred. The evidence to support the palliative use of second-line therapy is limited.⁶ In select patients, paclitaxel⁷ or cetuximab⁸ may be considered, especially if not previously treated with a similar class of agent.

[Continued on PN-C 2 of 2](#)

[References on PN-C 2 of 2](#)

Note: All recommendations are category 2A unless otherwise indicated.

Clinical Trials: NCCN believes that the best management of any cancer patient is in a clinical trial. Participation in clinical trials is especially encouraged.



PRINCIPLES OF CHEMOTHERAPY

Preferred combination chemotherapy regimens

TIP²

Paclitaxel 175 mg/m² IV over 3 hours on Day 1
Ifosfamide 1200 mg/m² IV over 2 hours on Days 1–3
Cisplatin 25 mg/m² IV over 2 hours on Days 1–3
Repeat every 3 to 4 weeks

5-FU + cisplatin⁴ (category 2B)

Continuous infusion 5-FU 1000 mg/m²/d IV on Days 1–5
Cisplatin 100 mg/m² IV on Day 1
Repeat every 3 to 4 weeks

Radiosensitizing agents and combinations⁹ (Chemoradiotherapy)

- Preferred
 - ▶ Cisplatin alone, or in combination with 5-FU
- Alternate options
 - ▶ Mitomycin C in combination with 5-FU
 - ▶ Capecitabine (for palliation)

References

1. Pettaway CA, Pagliaro L, Theodore C, Haas G. Treatment of visceral, unresectable, or bulky/unresectable regional metastases of penile cancer. *Urology* 2010;76:S58-65.
2. Pagliaro LC, Williams DL, Daliani D, et al. Neoadjuvant paclitaxel, ifosfamide, and cisplatin chemotherapy for metastatic penile cancer: a phase II study. *J Clin Oncol* 2010;28:3851-3857.
3. Hakenberg OW, Compérat EM, Minhas S, Necchi A, Protzel C, Watkin N; European Association of Urology. EAU guidelines on penile cancer: 2014 update. *Eur Urol* 2015;67:142-150.
4. Di Lorenzo G, Buonerba C, Federico P, et al. Cisplatin and 5-fluorouracil in inoperable, stage IV squamous cell carcinoma of the penis. *BJU Int* 2012;110(11 Pt B):E661-6.
5. Haas GP, Blumenstein BA, Gagliano RG, et al. Cisplatin, methotrexate and bleomycin for the treatment of carcinoma of the penis: a Southwest Oncology Group study. *J Urol* 1999;161:1823-1825.
6. Wang J, Pettaway CA, Pagliaro LC. Treatment for metastatic penile cancer after first-line chemotherapy failure: analysis of response and survival outcomes. *Urology* 2015;85:1104-1110.
7. Di Lorenzo G, Federico P, Buonerba C, et al. Paclitaxel in pretreated metastatic penile cancer: final results of a phase 2 study. *Eur Urol* 2011;60:1280-1284.
8. Carthon BC, Ng CS, Pettaway CA, Pagliaro LC. Epidermal growth factor receptor-targeted therapy in locally advanced or metastatic squamous cell carcinoma of the penis. *BJU Int* 2014;113:871-877.
9. Pagliaro LC, Crook J. Multimodality therapy in penile cancer: when and which treatments? *World J Urol* 2009;27:221-225.

Note: All recommendations are category 2A unless otherwise indicated.

Clinical Trials: NCCN believes that the best management of any cancer patient is in a clinical trial. Participation in clinical trials is especially encouraged.



NCCN Guidelines Version 1.2016 Staging Penile Cancer

Table 1
**American Joint Committee on Cancer (AJCC)
TNM Staging System for Penile Cancer (7th ed., 2010)**
Primary Tumor (T)

TX	Primary tumor cannot be assessed
T0	No evidence of primary tumor
Ta	Noninvasive verrucous carcinoma*
Tis	Carcinoma in situ
T1a	Tumor invades subepithelial connective tissue without lymph vascular invasion and is not poorly differentiated (i.e., grade 3-4)
T1b	Tumor invades subepithelial connective tissue with lymph vascular invasion or is poorly differentiated
T2	Tumor invades corpus spongiosum or cavernosum
T3	Tumor invades urethra
T4	Tumor invades other adjacent structures

*Note: Broad pushing penetration (invasion) is permitted; destructive invasion is against the diagnosis

Regional Lymph Nodes (N)

Clinical Stage Definition*

cNX	Regional lymph nodes cannot be assessed
cN0	No lymph node metastasis
cN1	Palpable mobile unilateral inguinal lymph node
cN2	Palpable mobile multiple or bilateral inguinal lymph nodes
cN3	Palpable fixed inguinal nodal mass or pelvic lymphadenopathy unilateral or bilateral

Pathologic Stage Definition*

pNX	Regional lymph nodes cannot be assessed
pN0	No regional lymph node metastasis
pN1	Metastasis in a single inguinal node
pN2	Metastasis in multiple or bilateral inguinal lymph nodes
pN3	Extranodal extension of lymph node metastasis or pelvic lymph node(s) unilateral or bilateral

*Note: Pathologic stage definition based on biopsy or surgical excision.

Distant Metastasis (M)

M0	No distant metastasis
M1	Distant metastasis

Used with the permission of the American Joint Committee on Cancer (AJCC), Chicago, Illinois. The original and primary source for this information is the AJCC Cancer Staging Manual, Seventh Edition (2010) published by Springer Science+Business Media, LLC (SBM). (For complete information and data supporting the staging tables, visit www.springer.com.) Any citation or quotation of this material must be credited to the AJCC as its primary source. The inclusion of this information herein does not authorize any reuse or further distribution without the expressed, written permission of Springer SBM, on behalf of the AJCC.

ANATOMIC STAGE/PROGNOSTIC GROUPS

Stage 0	Tis	N0	M0
	Ta	N0	M0
Stage I	T1a	N0	M0
Stage II	T1b	N0	M0
	T2	N0	M0
	T3	N0	M0
Stage IIIA	T1-3	N1	M0
Stage IIIB	T1-3	N2	M0
Stage IV	T4	Any N	M0
	Any T	N3	M0
	Any T	Any N	M1

Discussion

This discussion is being updated to correspond with the newly updated algorithm. Last updated 03/04/15

NCCN Categories of Evidence and Consensus

Category 1: Based upon high-level evidence, there is uniform NCCN consensus that the intervention is appropriate.

Category 2A: Based upon lower-level evidence, there is uniform NCCN consensus that the intervention is appropriate.

Category 2B: Based upon lower-level evidence, there is NCCN consensus that the intervention is appropriate.

Category 3: Based upon any level of evidence, there is major NCCN disagreement that the intervention is appropriate.

All recommendations are category 2A unless otherwise noted.

Table of Contents

Overview	MS-2
Literature Search Criteria and Guidelines Update Methodology	MS-2
Risk Factors	MS-2
Clinical Presentation	MS-3
Characterization and Clinical Staging	MS-3
Management of Primary Lesions	MS-4
Diagnosis	MS-4
NCCN Recommendations	MS-4

Tis or Ta	MS-4
T1G1-2	MS-4
T1G3-4 or T≥2	MS-4

Management of Regional Lymph NodesMS-5

Evaluation and Risk Stratification	MS-5
Dynamic Sentinel Node Biopsy	MS-6
Inguinal Lymph Node Dissection	MS-7
Modified Template Lymphadenectomy	MS-7
Delayed Inguinal Lymphadenectomy.....	MS-8
Unilateral Versus Bilateral Lymphadenectomy	MS-8
Pelvic Lymphadenectomy.....	MS-8
Chemotherapy.....	MS-8
NCCN Recommendations	MS-9
Non-Palpable Nodes.....	MS-9
Unilateral Palpable Nodes <4 cm.....	MS-9
Palpable Nodes ≥4 cm (fixed or mobile)	MS-9

SurveillanceMS-10

Recurrence.....MS-10

Metastatic Disease.....MS-10

SummaryMS-11

ReferencesMS-12

Overview

Squamous cell carcinoma (SCC) of the penis is a rare disease, representing 0.4% to 0.6% of all malignant neoplasms among men in the United States and Europe.¹ In 2015, the estimated number of new cases of penile and other male genital cancers in the United States was 1820, with 310 predicted cancer-specific deaths.² Incidence is higher (up to 10%) among men in the developing countries of Asia, Africa, and South America.³ The most common age of presentation is between 50 and 70 years.⁴ Early diagnosis is of utmost importance, as this is a disease that can result in devastating disfigurement and has a 5-year survival rate of approximately 50% (over 85% for patients with negative lymph nodes and 29%–40% for patients with positive nodes, with the lowest survival rates at 0% for patients with pelvic lymph node [PLN] involvement).⁵ As the rarity of this disease makes it difficult to perform prospective, randomized trials, the NCCN Panel relied on the experience of penile cancer experts and the best currently available evidence-based data to collectively lay down a foundation to help standardize the management of the malignancy.

Literature Search Criteria and Guidelines Update Methodology

Prior to the update of this version of the NCCN Guidelines for Penile Cancer, an electronic search of the PubMed database was performed to obtain key literature published between August 21, 2013 and August 21, 2014, using the following search term: penile cancer. The PubMed database was chosen as it remains the most widely used resource for medical literature and indexes only peer-reviewed biomedical literature.⁶

The search results were narrowed by selecting studies in humans published in English. Results were confined to the following article

types: Clinical Trial; Guideline; Meta-Analysis; Randomized Controlled Trial; Systematic Reviews; and Validation Studies.

The PubMed search resulted in 23 citations and their potential relevance was examined. The data from key PubMed articles as well as articles from additional sources deemed as relevant to these Guidelines and discussed by the panel have been included in this version of the Discussion section (eg, e-publications ahead of print, meeting abstracts). Recommendations for which high-level evidence is lacking are based on the panel's review of lower-level evidence and expert opinion.

The complete details of the Development and Update of the NCCN Guidelines are available on the NCCN [webpage](#).

Risk Factors

In the United States the median age of diagnosis is 68 years, with an increase in risk for males older than 50 years.⁷ Early detection is assisted by the ability to do a good physical exam. Phimosis may hinder the capability to properly inspect the areas of highest incidence—the glans, inner preputial layer, coronal sulcus, and shaft. Men with phimosis carry an increased risk for penile cancer of 25% to 60%.^{4,8,9} A review of penile SCC in the United States showed that 34.5% of patients had the primary lesion on the glans, 13.2% on the prepuce, and 5.3% in the shaft, with 4.5% overlapping and 42.5% unspecified.⁷ Other risk factors include balanitis, chronic inflammation, penile trauma, tobacco use, lichen sclerosus, poor hygiene, and a history of sexually transmitted disease(s), especially HIV and HPV.⁴ Overall, about 45% to 80% of penile cancers are related to HPV, with a strong correlation with types 16 and 18.^{4,8,10,11} There is an 8-fold increased risk for patients with HIV, which may correspond to a higher incidence of HPV among males with HIV.¹² Cigarette smokers are noted to be 3 to 4.5 times more likely

to develop penile cancer.^{10,13} Patients with lichen sclerosus are noted to have a 2% to 9% risk of developing penile carcinoma.¹⁴⁻¹⁶ Psoriasis patients undergoing psoralen plus ultraviolet A (PUVA) treatment have an increased penile cancer incidence of 286 times compared to the general population. Therefore, they should be shielded during treatment and any penile lesion should be closely monitored.¹⁷ A study of men with advanced penile SCC receiving systemic therapy identified visceral metastases and an ECOG performance score greater than or equal to 1 as poor prognostic factors for both overall survival and progression-free survival.¹⁸ Studies remain limited on predictive factors of prognosis in this patient population.

Clinical Presentation

Most often penile SCC presents as a palpable, visible lesion on the penis, which may be associated with penile pain, discharge, bleeding, or a foul odor if the patient delays seeking medical treatment. The lesion may be characterized as nodular, ulcerative, or fungating, and may be obscured by phimosis. The patient may exhibit signs of more advanced disease, including palpable nodes and/or constitutional symptoms (eg, fatigue, weight loss).

Characterization and Clinical Staging

SCC is the most common variant of penile cancer. Penile intraepithelial neoplasia (PIN) is a premalignant condition at high risk of developing into SCC of the penis.¹⁹ The AJCC recognizes four subtypes of SCC: verrucous, papillary squamous, warty, and basaloid.²⁰ The verrucous subtype is felt to be of low malignant potential, while other variants reported—adenosquamous and sarcomatoid variants—carry a worse prognosis.^{21,22} The primary lesion is further characterized by its growth pattern with superficial spread, nodular or vertical-phase growth, and verrucous pattern. In addition to the penile lesion, evaluation of lymph

nodes is also critical, as involvement of the inguinal lymph nodes (ILNs), the number and site of positive nodes, and extracapsular nodal involvement provide the strongest prognostic factors of survival.^{5,23}

The AJCC Tumor, Nodes, and Metastasis (TNM) system for penile carcinoma has been used for staging, with the most recent update published in 2010. It was initially introduced in 1968 and was subsequently revised in 1978, 1987, and 2002.^{20,24-27} In the 2010 update, the AJCC has made the distinction between clinical and pathologic staging while eliminating the difference between superficial and deep inguinal metastatic nodes.²⁰ Other changes to the 2010 TNM system include: T1 subdivided into T1a and T1b as determined by the presence or absence of lymphovascular invasion or poorly differentiated cancers; the T3 category is now limited to urethral invasion and T4 is limited to prostatic invasion; and stage II grouping includes T1b N0M0 as well as T2-3 N0M0 (see staging tables in the algorithm). A grading system for SCC of the penis based on degree of cell anaplasia is defined as: grade 1, well differentiated (no evidence of anaplasia); grade 2, moderately differentiated (<50% anaplasia); and grade 3, poorly differentiated (>50% anaplastic cells).²⁸ According to the AJCC, if no grading system is specified, a general system should be followed: GX, grade cannot be assessed; G1-3 as previously mentioned above; and G4, undifferentiated.²⁰ The overall degree of cellular differentiation with high-risk, poorly differentiated tumors is an important predictive factor for metastatic nodal involvement.²⁹ The AJCC also recommends collection of site-specific factors, including: the distinction between corpus spongiosum and corpus cavernosum involvement, the percentage of tumor that is poorly differentiated, the depth of invasion in verrucous carcinoma, the size of the largest lymph node metastasis, and HPV status.²⁰

Management of Primary Lesions

Diagnosis

Evaluation of the primary lesion, regional lymph nodes, and distant metastasis will dictate the appropriate and adequate management of SCC of the penis, beginning with the first evaluation at presentation and then throughout follow-up. Vital to the initial management is a good physical exam of the penile lesion(s) that remarks on the diameter of the lesion(s) or suspicious areas; location(s) on the penis; number of lesions; morphology of the lesion(s); whether the lesion(s) are papillary, nodular, ulcerous, or flat; and relationship with other structures including submucosal, urethra, corpora spongiosa, and/or corpora cavernosa. To complete the initial evaluation, a histologic diagnosis with a punch, excisional, or incisional biopsy is paramount in determining the treatment algorithm based on a pathologic diagnosis.^{20,30} This will provide information on the grade of the tumor, and will assist in the risk stratification of the patient for regional lymph node involvement.³⁰ MRI or ultrasound can be used to evaluate the depth of tumor invasion.³¹ For the evaluation of lymph nodes, see *Management of Regional Lymph Nodes*.

NCCN Recommendations

Tis or Ta

For patients with penile carcinoma *in situ* or noninvasive verrucous carcinoma, penis-preserving techniques may be utilized, including topical imiquimod (5%) or 5-FU cream, circumcision and wide local excision such as Mohs surgery, laser therapy (category 2B) using carbon dioxide or neodymium:yttrium-aluminum-garnet, and complete glansectomy (category 2B). Among these, topical therapy³²⁻³⁴ and excisional organ-sparing surgery³⁵ are the most widely used. Retrospective studies of laser therapy reported local recurrence rates of

around 18%, comparable to that of surgery, with good cosmetic and functional results.^{36,37} Glansectomy, removal of the glans penis, has also been studied with no recurrence observed in some cases.³⁸⁻⁴¹

T1G1-2

Careful consideration should be given to penile-preserving techniques if the patient is reliable in terms of compliance with close follow-up. These techniques include wide local excision as well as Mohs surgery as an option plus reconstructive surgery,⁴² laser therapy (category 2B),⁴³ and radiotherapy delivered as external beam radiation therapy (EBRT) or brachytherapy with interstitial implant (category 2B).⁴⁴⁻⁴⁸ Emphasis is placed again on patient selection and close follow-up, as the 2-year recurrence rate may reach up to 50%.⁴⁹ Studies have shown that surgical margins of 5 to 10 mm are as safe as 2-cm surgical margins, and 10- to 20-mm margins provide adequate tumor control.⁵⁰ Circumcision should always precede radiation therapy (RT) to prevent radiation-related complications.

T1G3-4 or T≥2

These lesions typically require more extensive surgical intervention with partial or total penectomy depending on the characteristics of the tumor and depth of invasion.³⁰ Intraoperative frozen sectioning is recommended to achieve negative surgical margins. If the tumor encompasses less than half of the glans and the patient agrees to very close observation, then a more conservative approach such as wide local excision or glansectomy may be considered. The patient should understand that there is an increased risk for recurrence and potential for a repeat wide local excision should a local recurrence be noted, provided there is no invasion of the corpora cavernosa.^{37,41} A clear and frank discussion should be had with the patient that a partial or total penectomy will likely be required should a larger or more invasive lesion be present.

The tumor size is an important factor when choosing RT as treatment. As the average length of the glans is about 4 cm, this serves as a cutpoint to reduce the risk of under-treating cavernosal lesions. In a study of 144 patients with penile cancer restricted to the glans treated by brachytherapy, larger tumors, especially those over 4 cm, are associated with higher risk of recurrence.⁵¹ A high, 10-year, cancer-specific survival rate of 92% was achieved in this series.

There was nonuniform consensus among NCCN Panelists on the use of RT as primary therapy due to scant data. RT alone is a category 2B recommendation, while RT with concurrent chemotherapy is a category 3 recommendation. RT should be given after circumcision has been performed.

For tumors smaller than 4 cm, brachytherapy with interstitial implant is preferred, but EBRT with or without chemotherapy is a viable option. Consider prophylactic ILN irradiation if selecting EBRT. For tumors 4 cm or larger, EBRT combined with chemotherapy may be used. Brachytherapy may still be appropriate in select cases, but careful monitoring is necessary as the risks of complications and failures increase.⁵² Crook and colleagues reported a 10-year cause-specific survival of 84% in 67 patients with T1-2 (select cases of T3) penile lesions treated with primary brachytherapy.⁴⁸

Post-surgical RT to the primary tumor site may be considered for positive margins.

Management of Regional Lymph Nodes

Evaluation and Risk Stratification

The presence and extent of regional ILN metastases has been identified as the single most important prognostic indicator in determining long-term survival in men with invasive penile SCC.²³

Evaluation of the groin and pelvis is an essential component of the metastatic workup of a patient. The involvement of the ILN can be clinically evident (ie, palpable vs. non-palpable), adding to the difficulty in management. Clinical exam for ILN involvement should attempt to evaluate and assess for palpability, number of inguinal masses, unilateral or bilateral localization, dimensions, mobility or fixation of nodes or masses, relationship to other structures (eg, skin, Cooper's ligaments), and edema of the penis, scrotum, and/or legs.^{53,54} Crossover drainage from left to right and vice versa does occur and is reproducible with lymphoscintigraphy.^{5,55} The physical exam should describe the diameter of node(s) or mass(es), unilateral or bilateral localization, number of nodes identified in each inguinal, and the relationship to other structures, particularly with respect to the mobility or fixation of the node(s) or mass(es) to adjacent structures and/or involvement of the overlying skin. Imaging for palpable disease by CT or MRI may be used to assess the size, extent, location, and structures that are in close proximity to the ILN, as well as the presence of pelvic and retroperitoneal lymph nodes and distant metastasis. CT and MRI are limited in patients with non-palpable disease.^{53,56} While studies have looked at the use of nanoparticle-enhanced MRI, PET/CT, and 18F-fluorodeoxyglucose (FDG) PET/CT, the small sample sizes require validation in larger prospective studies.⁵⁷⁻⁶⁰ When considering one imaging modality to evaluate the stage of the primary lesion and lymph node status, MRI appears to be the best choice to enhance the physical exam in patients where the inguinal region is difficult to assess (eg, morbidity, previous chemotherapy/radiotherapy).^{57,61}

Consideration needs to be given to whether or not the primary lesion demonstrated any adverse prognostic factors. If one or more of these high-risk features is present, then pathologic ILN staging must be performed. Up to 25% of patients with non-palpable lymph nodes harbor

micrometastases.²⁸ Therefore, several predictive factors have been evaluated to help predict the presence of occult lymph node metastasis.^{49,62} Slaton et al²⁸ concluded that patients with pathologic stage T2 or greater disease were at significant risk (42%–80%) of nodal metastases if they exhibited greater than 50% poorly differentiated cancer and/or vascular invasion, and therefore should be recommended to undergo an inguinal lymph node dissection (ILND).^{5,28} These factors can then further define patients into low-, intermediate-, and high-risk groups for lymph node metastasis.^{21,63,64} The European Association of Urology determined risk stratification groups for patients with non-palpable ILNs, and validated this in both uni- and multivariate analyses of prognostic factors. Patients can be stratified based on stage and/or grade into risk groups based on the likelihood of harboring occult node-positive disease, with the low-risk group defined as patients with Tis, Ta, or T1a disease, the intermediate group as those with T1b disease (lymphovascular invasion), and the high-risk group as those with T2 or G3/G4 disease.^{54,63}

There is a paucity of data regarding the predictive value of lymph node removal. A singular study suggests that disease-specific survival following radical lymphadenectomy can be predicted by the lymph node count and lymph node density.⁶⁵ Removal of greater than or equal to 16 lymph nodes in patients with pathologic negative nodes was associated with a significantly longer disease-specific survival rate ($P < 0.05$). Furthermore, the 5-year disease-free survival in patients with pathologic positive nodes was 81.2% in patients with lymph node density greater than 16% compared to 24.4% in patients with less than 16% lymph node density ($P < 0.001$).⁶⁵ Although this study suggests that lymph node count and density may be useful in predicting disease-specific survival, a larger validation study is necessary to support these preliminary data.

Dynamic Sentinel Node Biopsy

The work by Cabanas used lymphangiograms and anatomic dissections to evaluate the sentinel lymph node drainage for penile cancer with non-palpable ILNs.⁶⁶ This technique has been shown to have false-negative rates as high as 25%; therefore, it is no longer recommended.^{54,67} Advancements have been made with the dynamic sentinel node biopsy (DSNB) technique developed for penile cancer by the Netherlands Cancer Institute using lymphoscintigraphy and performed with technetium-99m–labeled nanocolloid and patent blue dye isosulfan blue.^{68,69} Initially, this technique was associated with a low sensitivity and high false-negative rate (16%–43%).⁷⁰⁻⁷³ Refinement of the technique to include serial sectioning and immunohistochemical staining of pathologic specimens, preoperative ultrasonography with and without fine needle aspiration (FNA) cytology, and exploration of groins in which no sentinel node is visualized on intraoperative assessment decreased the false-negative rate from 19% to only 5%.^{68,74} Using FNA with ultrasound can increase the diagnostic yield in metastases greater than 2 mm in diameter.^{56,75} Crashaw et al⁷⁶ used ultrasound with DSNB and noted improved accuracy in identifying patients with occult lymph node metastases. With modification of the NCI protocol, Hadway et al⁷⁷ were able to achieve a similar false-negative rate (5%) with an 11-month follow-up. A recent observational cohort study of 1000 patients treated between 1956 and 2012, suggests that DSNB can improve 5-year survival in patients with clinically node-negative groins.⁷⁸ Data in this study showed that patients treated prior to 1994 (the year DSNB was incorporated into treatment) had an 82% 5-year survival compared to the 91% 5-year survival seen in patients treated between 1994 and 2012 ($P = 0.021$). However, there are several limitations of this study including the possibility that improved staging resulted in more patients being grouped in a higher risk group. Therefore, incorporation of DSNB into treatment guidelines should be

limited to centers with experience. Secondary to the technical challenges associated with DSNB, to be accurate and reliable, it is recommended that DSNB be performed at tertiary care referral centers where at least 20 procedures are done per year.^{68,79} It should be noted that DSNB is not recommended in patients with palpable ILNs.⁵³

Inguinal Lymph Node Dissection

The most frequent sites of metastasis from penile cancer are the ILNs, typically presenting as palpable inguinal lymphadenopathy. The management of ILNs by ILND has been fraught with great fears of surgical morbidity.^{54,80} Early treatment of lymph node involvement has been shown to have a positive impact on survival, except if the patient has bulky nodal spread or other sites of metastases.^{81,82} Palpable lymphadenopathy at the time of diagnosis does not warrant an immediate ILND. Of the patients with palpable disease, 30% to 50% will be secondary to inflammatory lymph node swelling instead of metastatic disease.⁶² Although the distinction between reactive lymph nodes and metastatic disease has traditionally been done with a 6-week course of antibiotics, percutaneous needle biopsy is becoming the favored approach among many penile cancer experts for patients with palpable nodes.^{5,53} In this setting, antibiotics are useful if the patient has a suspected underlying cellulitis at the site of palpable inguinal lymphadenopathy and future site of ILND.^{5,53,83}

The boundaries of the standard, full-template ILND (ie, Daseler's quadrilateral area) are: superiorly, the inguinal ligament; inferiorly, the fossa ovalis; laterally, the medical border of sartorius muscle; and medially, the lateral edge of adductor longus muscle.⁸³ Historically, it has been recommended to keep the patient on bed rest for 48 to 72 hours, especially after myocutaneous flaps or repair of large skin defects, although the necessity for this is debatable and not

corroborated with rigorous scientific data. Closed suction drains are placed at surgery and are typically removed when drainage is less than 50 to 100 mL per day.^{83,84} Consideration should be given to keeping the patient on a suppressive dose of an oral cephalosporin (or other gram-positive, broad-spectrum antibiotic) for several days to weeks postoperatively in an attempt to decrease the risk of wound-related issues and minimize the risk for overall complications. However, the data supporting this treatment approach are very limited.⁸³

Modified Template Lymphadenectomy

In attempts to decrease the morbidity associated with standard ILND, a modified template lymphadenectomy has been proposed that uses a shorter skin incision, limiting the field of inguinal dissection by excluding the area lateral to the femoral artery and caudal to the fossa ovalis, with preservation of the saphenous vein and elimination of the need to transpose the sartorius muscle while providing an adequate therapeutic effect. This technique is commonly reserved for patients with a primary tumor that places them at increased risk for inguinal metastasis but with clinically negative groins on examination.^{83,85} The modified technique has shown a decrease in complications. Contemporary modified ILND should include the central and superior zones of the inguinal region, as these sections were not included in the dissection leading to a false-negative rate of 15%.^{86,87} It is important to note that if nodal involvement is detected on frozen section, the surgical procedure should be converted to a standard, full-template lymphadenectomy. A standard full-template lymphadenectomy should be considered in all patients who have resectable inguinal lymphadenopathy. However, studies would favor neoadjuvant chemotherapy prior to proceeding with surgery, particularly in patients with bulky ILN metastases (ie, fixed nodes or nodal diameter ≥ 3 cm).^{88,89} Generally, ILND is performed within 4 to 6 weeks following the completion of systemic chemotherapy to allow



patient recovery while minimizing the risk of cancer progression post-chemotherapy.

Delayed Inguinal Lymphadenectomy

Since data exist that suggest men with clinically negative groins undergoing immediate ILND have better survival outcomes than men undergoing delayed ILND once their groins are clinically positive, it is recommended that in most circumstances men with high-risk penile tumors should undergo immediate ILND. However, patients with lower-risk tumors who are undergoing active surveillance or high-risk men who refuse immediate ILND may experience an inguinal nodal recurrence at some time point during follow-up. The median time to inguinal recurrence after treatment of the primary penile tumor is approximately 6 months, with 90% occurring by year 3 and 100% by year 5.⁹⁰⁻⁹²

Unilateral Versus Bilateral Lymphadenectomy

In patients with high-risk features that do not have palpable lymph nodes, bilateral lymphadenectomy is generally performed, because it is not possible to predict the laterality of inguinal nodal metastasis based on the location of the tumor on the penis. Similarly, in patients who have a unilateral palpable node, about 30% will have contralateral positive nodes that are not palpable.⁹³ Therefore, bilateral lymphadenectomy should be considered the standard of care in patients undergoing immediate ILND for high-risk penile tumors or because of palpable nodes. When there is a delayed (>1 year after treatment of the primary penile tumor) inguinal recurrence of cancer, it is usually unilateral, and some authors have suggested that ipsilateral ILND is adequate while others have advocated for bilateral ILND in this circumstance.⁵

Pelvic Lymphadenectomy

Approximately 20% to 30% of patients with positive ILNs will also have cancer within PLNs. Interestingly, penile tumors do not appear to metastasize to the PLNs without first affecting the inguinal node echelon (ie, no skip lesions).^{66,92} Patients who have only one positive inguinal node have a risk of pelvic nodal involvement of less than 5% as reported by the Netherlands Cancer Institute.⁹⁴ The presence of cancer within the PLN is associated with a very poor 5-year survival rate that is typically of less than 10%. Based on these prior reports, pelvic lymphadenectomy (resection of external iliac, internal iliac, and obturator lymph nodes) is recommended in patients with 2 or more positive ILNs and in the clinical context of high-grade cancer within the ILN pathologic specimen. Pelvic lymph node dissection (PLND) can be conducted during the same operative session as the ILND if the intraoperative frozen section is positive in 2 or more of the inguinal nodes (raising the importance of obtaining a lymph node count intraoperatively) or in a delayed staged fashion based on the pathologic features of the ILND specimen.^{95,96}

One area of controversy is whether the PLND should be performed ipsilaterally or bilaterally in patients with unilateral positive ILNs. Crossover (right to left or left to right) of inguinal to pelvic nodes has not been well studied; hence, both approaches are feasible and left at the discretion of the surgeon based on case-specific characteristics.

Chemotherapy

A patient who presents with resectable bulky disease will rarely be cured with a single treatment modality. Consideration should be given to neoadjuvant chemotherapy if ILNs are greater than or equal to 4 cm. Patients who may benefit from surgical consolidation would be those who had stable, partial, or complete response following systemic

chemotherapy, thus increasing their potential for disease-free survival.^{88,89} Pagliaro et al⁹⁷ performed a phase II clinical trial in 30 patients, with stage N2 or N3 (stage III or stage IV) penile cancer without distant metastases, receiving neoadjuvant chemotherapy with paclitaxel, ifosfamide, and cisplatin. In this series, 50% of patients were noted to have a clinically meaningful response and 22 patients (73.3%) subsequently underwent surgery. There was an improved time to progression and overall survival associated with chemotherapy responsiveness ($P < .001$ and $P = .001$, respectively), absence of bilateral residual tumor ($P = .002$ and $P = .017$, respectively), and absence of extranodal extension ($P = .001$ and $P = .004$, respectively) or skin involvement ($P = .009$ and $P = .012$, respectively).

NCCN Recommendations

Non-Palpable Nodes

Most low-risk patients are followed with a surveillance protocol, as the probability of occult micrometastases in ILNs is less than 17%.^{63,91} For patients at high or intermediate risk, a modified or radical inguinal lymphadenectomy is strongly recommended as occult metastatic disease ranges between 68% and 73%.^{49,63,91} If positive nodes are present on the frozen section, then a superficial and deep inguinal lymphadenectomy should be performed (with consideration of a PLND).

As DSNB is currently not widely practiced in the United States, it is a category 2B option for examining non-palpable nodes to determine the need for a modified lymphadenectomy in place of predictive factors.^{98,99} This technique should be performed in tertiary care referral centers with substantial experience. DSNB is not recommended for Ta tumors, as observation alone of the ILNs is sufficient for these well-differentiated lesions in the absence of palpable adenopathy.

Unilateral Palpable Nodes <4 cm

Lymph node biopsy is considered standard for these patients if no risk feature is present in the primary lesion. Risk features include T1 tumors; high grade, lymphovascular invasion; and poor differentiation in more than half of the tumor cells. The NCCN Panel recommends omitting the procedure for patients with high-risk primary lesions to avoid delay of lymphadenectomy. A negative lymph node biopsy should be confirmed with an excisional biopsy. Alternatively, careful surveillance may be considered following a negative lymph node biopsy. Positive findings from either procedure warrant an immediate ILND.

Palpable Nodes ≥4 cm (fixed or mobile)

Large, unilateral, mobile nodes should first be confirmed by needle biopsy. A negative needle biopsy should be confirmed by an excisional biopsy. Patients with confirmed nodes are amenable to standard or modified ILND. Neoadjuvant chemotherapy should be considered before surgery. No further treatment is necessary if no viable tumor elements are detected in the surgical specimen. Patients with viable disease in a single node after undergoing systemic chemotherapy can be considered for a PLND, but the evidence supporting this approach is sparse. Postoperative radiotherapy or chemoradiotherapy may be considered in patients after PLND, particularly in the setting of a positive surgical margin, viable cancer in multiple inguinal or pelvic lymph nodes, and/or presence of extranodal extension on the final pathologic specimen.

In the case of multiple or bilateral ILNs, patients should undergo a needle biopsy of the lymph nodes regardless of whether these are mobile or fixed. A negative result should be confirmed with excisional biopsy. If results are again negative, the patient should be closely followed. Patients with a positive aspiration or biopsy should receive neoadjuvant systemic chemotherapy followed by ILND and PLND.

Patients with abnormal PLNs on imaging (CT or MRI) are stratified by resectability. Nonsurgical candidates should be treated with chemoradiation. Patients with resectable disease should receive neoadjuvant systemic chemotherapy with consideration of a confirmatory percutaneous biopsy or PET/CT. Patients who respond to therapy or become stable should undergo bilateral superficial and deep ILND and bilateral PLND if deemed resectable. Patients with disease that progresses may receive additional systemic chemotherapy with consideration of local-field radiation or participation in a clinical trial.

Surveillance

Initial treatment of the primary tumor and lymph nodes dictates the follow-up schedule (see algorithm). A large retrospective review of 700 patients found that penile-sparing therapies carry a significantly higher risk of local recurrence (28%) than partial or total penectomy (5%) and thus require closer surveillance.⁹² Patients without nodal involvement had a regional recurrence rate of 2% compared to 19% for patients with node-positive disease. Of all recurrences, 92% were detected within 5 years of primary treatment.

Follow-up for all patients includes a clinical exam of the penis and inguinal region. Imaging is not routinely indicated for early disease (except for obese patients or patients who have undergone inguinal surgery since a physical exam may be challenging), but may be used upon abnormal findings. For patients with N2 or N3 disease, imaging of the chest, abdomen, and pelvic area is recommended.

Recurrence

Invasion of the corpora cavernosa is an adverse finding after initial organ-sparing treatment that warrants partial or total penectomy.^{100,101}

For primary tumor recurrences without corpora cavernosa infiltration, repeat penile-sparing options can be considered (category 2B).

A recurrence in the inguinal region carries a poor prognosis (median survival, <6 months) and optimal management remains elusive. Possible salvage options include systemic chemotherapy, EBRT, surgery, or a combination thereof.^{53,102} A recent study suggests that salvage ILND may be beneficial in patients with penile cancer with locally recurrent ILN metastases.¹⁰³ While potentially curative, patients must be advised of the high incidence of postoperative complications.¹⁰³

Metastatic Disease

Imaging of the abdomen and pelvis should be obtained when metastasis is suspected to evaluate for pelvic and/or retroperitoneal lymph nodes. PLN metastasis is an ominous finding, with a 5-year survival rate of 0% to 66% for all cases and 17% to 54% for microscopic invasion only, with a mean 5-year survival of approximately 10%.^{5,104-108} In patients with ILN metastases, 20% to 30% will have PLN metastases.⁵ This can be further characterized such that if 2 to 3 ILNs are involved, there is a 23% probability of PLN involvement. With involvement of 3 or more ILNs, this probability increases to 56%.¹⁰⁹

Lughezzani et al⁹⁵ identified three independent predictors of PLN metastases that included the number of inguinal metastases (OR, 1.92; $P < 0.001$), the diameter of the metastases (OR, 1.03; $P = 0.001$), and extranodal extension (OR, 8.01; $P < 0.001$). Similar to previous studies, patients with 3 or more ILN metastases had a 4.77-fold higher risk of PLN metastasis. An ILN metastasis diameter of 30 mm or greater correlated with a 2.53-fold higher risk of PLN metastasis. Patients who showed no risk factors had a 0% risk of metastasis, suggesting that this group may not require PLND.⁹⁵



NCCN Guidelines Version 1.2016

Penile Cancer

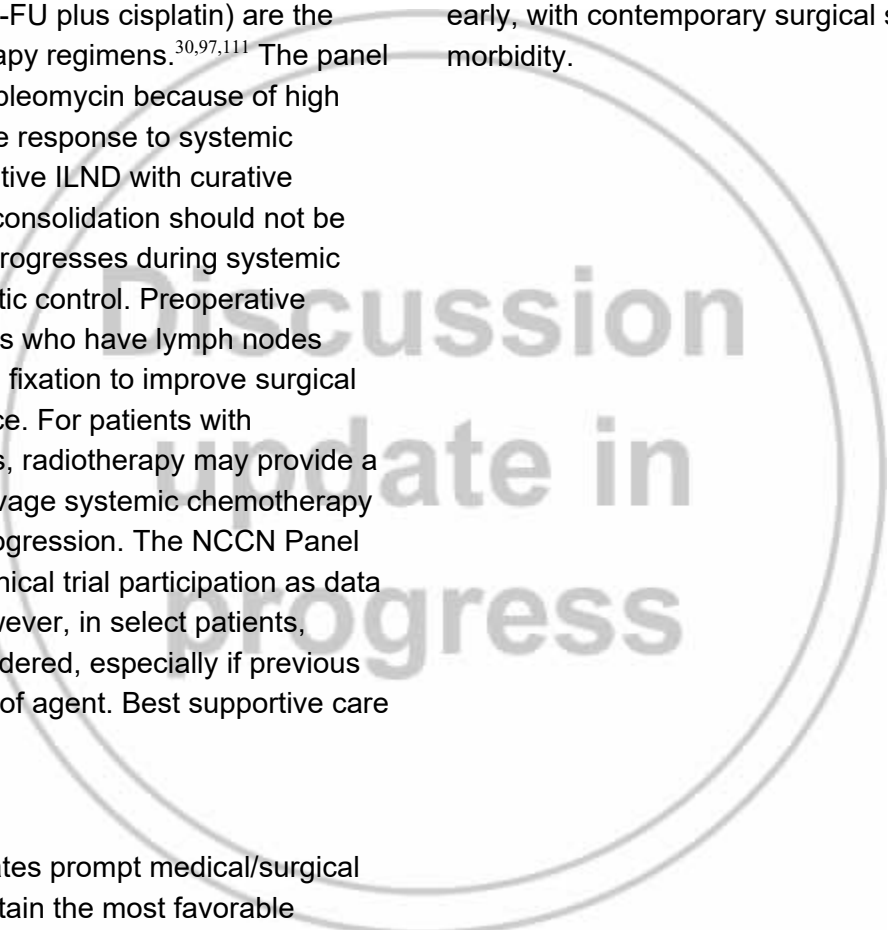
Pettaway et al¹¹⁰ evaluated the treatment options for stage IV penile cancer—clinical stage N3 (deep inguinal nodes or pelvic nodes) or M1 disease (distant metastases)—including chemotherapy, radiotherapy, and inguinal lymphadenectomy. Cisplatin-based regimens (paclitaxel, ifosfamide, and cisplatin or alternatively 5-FU plus cisplatin) are the most active first-line systemic chemotherapy regimens.^{30,97,111} The panel did not recommend regimens containing bleomycin because of high toxicity.¹¹² Patients with a proven objective response to systemic chemotherapy are amenable to consolidative ILND with curative potential or palliation. However, surgical consolidation should not be performed on patients with disease that progresses during systemic chemotherapy except for local symptomatic control. Preoperative radiotherapy may also be given to patients who have lymph nodes greater than or equal to 4 cm without skin fixation to improve surgical resectability and decrease local recurrence. For patients with unresectable inguinal or bone metastases, radiotherapy may provide a palliative benefit after chemotherapy. Salvage systemic chemotherapy may also be considered upon disease progression. The NCCN Panel strongly recommends consideration of clinical trial participation as data are limited in the second-line setting. However, in select patients, paclitaxel¹¹³ or cetuximab¹¹⁴ may be considered, especially if previous treatments did not include a similar class of agent. Best supportive care remains an option for advanced cases.

Summary

SCC of the penis is a disease that mandates prompt medical/surgical intervention and patient compliance to obtain the most favorable outcomes. A thorough history and physical is the initial step in this process, followed by a biopsy of the primary lesion to establish a pathologic diagnosis. Accurate clinical staging allows for a comprehensive treatment approach to be devised, thus optimizing

therapeutic efficacy and minimizing treatment-related morbidity.

Prognostic factors help predict if lymph node metastases are suspect in the absence of any palpable inguinal lymphadenopathy. When clinically indicated, an ILND has curative potential, particularly when performed early, with contemporary surgical series demonstrating its reduced morbidity.



References

- Pettaway CA, Lynch D, Jr, Davis D. Tumors of the Penis. In: Wein AJ, Kavoussi L, Novick AC, et al., eds. Campbell-Walsh Urology (ed 9). Philadelphia: Saunders; 2007:959-992.
- Siegel RL, Miller KD, Jemal A. Cancer statistics, 2015. *CA Cancer J Clin* 2015;65:5-29. Available at: <http://www.ncbi.nlm.nih.gov/pubmed/25559415>.
- Curado MP, Edwards B, Shin HR, et al. eds. Cancer Incidence in Five Continents. Vol. IX. Lyon: IARC Scientific; 2007. Available at: <http://www.iarc.fr/en/publications/pdfs-online/epi/sp160/Ci5vol9.pdf>. Accessed February 24, 2015.
- Pow-Sang MR, Ferreira U, Pow-Sang JM, et al. Epidemiology and natural history of penile cancer. *Urology* 2010;76:S2-6. Available at: <http://www.ncbi.nlm.nih.gov/pubmed/20691882>.
- Horenblas S. Lymphadenectomy for squamous cell carcinoma of the penis. Part 2: the role and technique of lymph node dissection. *BJU Int* 2001;88:473-483. Available at: <http://www.ncbi.nlm.nih.gov/pubmed/11589660>.
- U.S. National Library of Medicine-Key MEDLINE® Indicators. Available at: http://www.nlm.nih.gov/bsd/bsd_key.html. Accessed July 23, 2014.
- Hernandez BY, Barnholtz-Sloan J, German RR, et al. Burden of invasive squamous cell carcinoma of the penis in the United States, 1998-2003. *Cancer* 2008;113:2883-2891. Available at: <http://www.ncbi.nlm.nih.gov/pubmed/18980292>.
- Dillner J, von Krogh G, Horenblas S, Meijer CJ. Etiology of squamous cell carcinoma of the penis. *Scand J Urol Nephrol Suppl* 2000:189-193. Available at: <http://www.ncbi.nlm.nih.gov/pubmed/11144896>.
- Sufrin G, Huben R. Benign and malignant lesions of the penis. In: JY G, ed. *Adult and Pediatric Urology* (ed 2). Chicago: Year Book Medical Publisher; 1991:1643.
- Daling JR, Madeleine MM, Johnson LG, et al. Penile cancer: importance of circumcision, human papillomavirus and smoking in situ and invasive disease. *Int J Cancer* 2005;116:606-616. Available at: <http://www.ncbi.nlm.nih.gov/pubmed/15825185>.
- Sarkar FH, Miles BJ, Plieth DH, Crissman JD. Detection of human papillomavirus in squamous neoplasm of the penis. *J Urol* 1992;147:389-392. Available at: <http://www.ncbi.nlm.nih.gov/pubmed/1310122>.
- Engels EA, Pfeiffer RM, Goedert JJ, et al. Trends in cancer risk among people with AIDS in the United States 1980-2002. *AIDS* 2006;20:1645-1654. Available at: <http://www.ncbi.nlm.nih.gov/pubmed/16868446>.
- Maden C, Sherman KJ, Beckmann AM, et al. History of circumcision, medical conditions, and sexual activity and risk of penile cancer. *J Natl Cancer Inst* 1993;85:19-24. Available at: <http://www.ncbi.nlm.nih.gov/pubmed/8380060>.
- Depasquale I, Park AJ, Bracka A. The treatment of balanitis xerotica obliterans. *BJU Int* 2000;86:459-465. Available at: <http://www.ncbi.nlm.nih.gov/pubmed/10971272>.
- Micali G, Nasca MR, Innocenzi D, Schwartz RA. Penile cancer. *J Am Acad Dermatol* 2006;54:369-391. Available at: <http://www.ncbi.nlm.nih.gov/pubmed/16488287>.
- Barbagli G, Palminteri E, Mirri F, et al. Penile carcinoma in patients with genital lichen sclerosis: a multicenter survey. *J Urol* 2006;175:1359-1363. Available at: <http://www.ncbi.nlm.nih.gov/pubmed/16515998>.

17. Stern RS. Genital tumors among men with psoriasis exposed to psoralens and ultraviolet A radiation (PUVA) and ultraviolet B radiation. The Photochemotherapy Follow-up Study. *N Engl J Med* 1990;322:1093-1097. Available at: <http://www.ncbi.nlm.nih.gov/pubmed/2320078>.
18. Pond GR, Di Lorenzo G, Necchi A, et al. Prognostic risk stratification derived from individual patient level data for men with advanced penile squamous cell carcinoma receiving first-line systemic therapy. *Urol Oncol* 2014;32:501-508. Available at: <http://www.ncbi.nlm.nih.gov/pubmed/24332646>.
19. Bleeker MCG, Heideman DAM, Snijders PJF, et al. Penile cancer: epidemiology, pathogenesis and prevention. *World J Urol* 2009;27:141-150. Available at: <http://www.ncbi.nlm.nih.gov/pubmed/18607597>.
20. Penis. In: Edge SB, Byrd DR, Compton CC, et al., eds. *AJCC Cancer Staging Manual* (ed 7). New York: Springer; 2010:447.
21. Cubilla AL, Reuter V, Velazquez E, et al. Histologic classification of penile carcinoma and its relation to outcome in 61 patients with primary resection. *Int J Surg Pathol* 2001;9:111-120. Available at: <http://www.ncbi.nlm.nih.gov/pubmed/11484498>.
22. Guimaraes GC, Cunha IW, Soares FA, et al. Penile squamous cell carcinoma clinicopathological features, nodal metastasis and outcome in 333 cases. *J Urol* 2009;182:528-534. Available at: <http://www.ncbi.nlm.nih.gov/pubmed/19524964>.
23. Ficarra V, Akduman B, Bouchot O, et al. Prognostic factors in penile cancer. *Urology* 2010;76:S66-73. Available at: <http://www.ncbi.nlm.nih.gov/pubmed/20691887>.
24. Barocas DA, Chang SS. Penile cancer: clinical presentation, diagnosis, and staging. *Urol Clin North Am* 2010;37:343-352. Available at: <http://www.ncbi.nlm.nih.gov/pubmed/20674691>.
25. Leijte JAP, Gallee M, Antonini N, Horenblas S. Evaluation of current TNM classification of penile carcinoma. *J Urol* 2008;180:933-938. Available at: <http://www.ncbi.nlm.nih.gov/pubmed/18635216>.
26. Leijte JAP, Horenblas S. Shortcomings of the current TNM classification for penile carcinoma: time for a change? *World J Urol* 2009;27:151-154. Available at: <http://www.ncbi.nlm.nih.gov/pubmed/18690458>.
27. Sobin LH, Wittekind C, International Union against Cancer. *TNM Classification of Malignant Tumours* (ed 6). New York: Wiley-Liss; 2002.
28. Slaton JW, Morgenstern N, Levy DA, et al. Tumor stage, vascular invasion and the percentage of poorly differentiated cancer: independent prognosticators for inguinal lymph node metastasis in penile squamous cancer. *J Urol* 2001;165:1138-1142. Available at: <http://www.ncbi.nlm.nih.gov/pubmed/11257655>.
29. Velazquez EF, Ayala G, Liu H, et al. Histologic grade and perineural invasion are more important than tumor thickness as predictor of nodal metastasis in penile squamous cell carcinoma invading 5 to 10 mm. *Am J Surg Pathol* 2008;32:974-979. Available at: <http://www.ncbi.nlm.nih.gov/pubmed/18460979>.
30. Pizzocaro G, Algaba F, Horenblas S, et al. EAU penile cancer guidelines 2009. *Eur Urol* 2010;57:1002-1012. Available at: <http://www.ncbi.nlm.nih.gov/pubmed/20163910>.
31. Lont AP, Besnard APE, Gallee MPW, et al. A comparison of physical examination and imaging in determining the extent of primary penile carcinoma. *BJU Int* 2003;91:493-495. Available at: <http://www.ncbi.nlm.nih.gov/pubmed/12656901>.
32. Choi JW, Choi M, Cho KH. A case of erythroplasia of queyrat treated with imiquimod 5% cream and excision. *Ann Dermatol* 2009;21:419-422. Available at: <http://www.ncbi.nlm.nih.gov/pubmed/20523838>.

33. Schroeder TL, Sengelmann RD. Squamous cell carcinoma in situ of the penis successfully treated with imiquimod 5% cream. *J Am Acad Dermatol* 2002;46:545-548. Available at: <http://www.ncbi.nlm.nih.gov/pubmed/11907505>.
34. Taliaferro SJ, Cohen GF. Bowen's disease of the penis treated with topical imiquimod 5% cream. *J Drugs Dermatol* 2008;7:483-485. Available at: <http://www.ncbi.nlm.nih.gov/pubmed/18505144>.
35. Feldman AS, McDougal WS. Long-term outcome of excisional organ sparing surgery for carcinoma of the penis. *J Urol* 2011;186:1303-1307. Available at: <http://www.ncbi.nlm.nih.gov/pubmed/21862071>.
36. Bandieramonte G, Colecchia M, Mariani L, et al. Penoscopically controlled CO2 laser excision for conservative treatment of in situ and T1 penile carcinoma: report on 224 patients. *Eur Urol* 2008;54:875-882. Available at: <http://www.ncbi.nlm.nih.gov/pubmed/18243513>.
37. Horenblas S, van Tinteren H, Delemarre JF, et al. Squamous cell carcinoma of the penis. II. Treatment of the primary tumor. *J Urol* 1992;147:1533-1538. Available at: <http://www.ncbi.nlm.nih.gov/pubmed/1593683>.
38. Morelli G, Pagni R, Mariani C, et al. Glansectomy with split-thickness skin graft for the treatment of penile carcinoma. *Int J Impot Res* 2009;21:311-314. Available at: <http://www.ncbi.nlm.nih.gov/pubmed/19458620>.
39. O'Kane HF, Pahuja A, Ho KJ, et al. Outcome of glansectomy and skin grafting in the management of penile cancer. *Adv Urol* 2011;2011:240824. Available at: <http://www.ncbi.nlm.nih.gov/pubmed/21603193>.
40. Pietrzak P, Corbishley C, Watkin N. Organ-sparing surgery for invasive penile cancer: early follow-up data. *BJU Int* 2004;94:1253-1257. Available at: <http://www.ncbi.nlm.nih.gov/pubmed/15610100>.
41. Hatzichristou DG, Apostolidis A, Tzortzis V, et al. Glansectomy: an alternative surgical treatment for Buschke-Lowenstein tumors of the penis. *Urology* 2001;57:966-969. Available at: <http://www.ncbi.nlm.nih.gov/pubmed/11337304>.
42. Bissada NK, Yakout HH, Fahmy WE, et al. Multi-institutional long-term experience with conservative surgery for invasive penile carcinoma. *J Urol* 2003;169:500-502. Available at: <http://www.ncbi.nlm.nih.gov/pubmed/12544296>.
43. Frimberger D, Hungerhuber E, Zaak D, et al. Penile carcinoma. Is Nd:YAG laser therapy radical enough? *J Urol* 2002;168:2418-2421. Available at: <http://www.ncbi.nlm.nih.gov/pubmed/12441930>.
44. Azrif M, Logue JP, Swindell R, et al. External-beam radiotherapy in T1-2 N0 penile carcinoma. *Clin Oncol (R Coll Radiol)* 2006;18:320-325. Available at: <http://www.ncbi.nlm.nih.gov/pubmed/16703750>.
45. Crook J, Grimard L, Tsihlias J, et al. Interstitial brachytherapy for penile cancer: an alternative to amputation. *J Urol* 2002;167:506-511. Available at: <http://www.ncbi.nlm.nih.gov/pubmed/11792907>.
46. Rozan R, Albuissou E, Giraud B, et al. Interstitial brachytherapy for penile carcinoma: a multicentric survey (259 patients). *Radiother Oncol* 1995;36:83-93. Available at: <http://www.ncbi.nlm.nih.gov/pubmed/7501816>.
47. Zouhair A, Coucke PA, Jeanneret W, et al. Radiation therapy alone or combined surgery and radiation therapy in squamous-cell carcinoma of the penis? *Eur J Cancer* 2001;37:198-203. Available at: <http://www.ncbi.nlm.nih.gov/pubmed/11166146>.
48. Crook J, Ma C, Grimard L. Radiation therapy in the management of the primary penile tumor: an update. *World J Urol* 2009;27:189-196. Available at: <http://www.ncbi.nlm.nih.gov/pubmed/18636264>.
49. Horenblas S, van Tinteren H. Squamous cell carcinoma of the penis. IV. Prognostic factors of survival: analysis of tumor, nodes and

metastasis classification system. J Urol 1994;151:1239-1243. Available at: <http://www.ncbi.nlm.nih.gov/pubmed/8158767>.

50. Minhas S, Kayes O, Hegarty P, et al. What surgical resection margins are required to achieve oncological control in men with primary penile cancer? BJU Int 2005;96:1040-1043. Available at: <http://www.ncbi.nlm.nih.gov/pubmed/16225525>.

51. de Crevoisier R, Slimane K, Sanfilippo N, et al. Long-term results of brachytherapy for carcinoma of the penis confined to the glans (N- or NX). Int J Radiat Oncol Biol Phys 2009;74:1150-1156. Available at: <http://www.ncbi.nlm.nih.gov/pubmed/19395183>.

52. Crook J, Jezioranski J, Cygler JE. Penile brachytherapy: technical aspects and postimplant issues. Brachytherapy 2010;9:151-158. Available at: <http://www.ncbi.nlm.nih.gov/pubmed/19854685>.

53. Heyns CF, Fleshner N, Sangar V, et al. Management of the lymph nodes in penile cancer. Urology 2010;76:43-57. Available at: <http://www.ncbi.nlm.nih.gov/pubmed/20691885>.

54. Solsona E, Algaba F, Horenblas S, et al. EAU Guidelines on Penile Cancer. Eur Urol 2004;46:1-8. Available at: <http://www.ncbi.nlm.nih.gov/pubmed/15183542>.

55. Kroon BK, Valdes Olmos RA, van Tinteren H, et al. Reproducibility of lymphoscintigraphy for lymphatic mapping in patients with penile carcinoma. J Urol 2005;174:2214-2217. Available at: <http://www.ncbi.nlm.nih.gov/pubmed/16280766>.

56. Hughes B, Leijte J, Shabbir M, et al. Non-invasive and minimally invasive staging of regional lymph nodes in penile cancer. World J Urol 2009;27:197-203. Available at: <http://www.ncbi.nlm.nih.gov/pubmed/18594830>.

57. Mueller-Lisse UG, Scher B, Scherr MK, Seitz M. Functional imaging in penile cancer: PET/computed tomography, MRI, and sentinel lymph

node biopsy. Curr Opin Urol 2008;18:105-110. Available at: <http://www.ncbi.nlm.nih.gov/pubmed/18090498>.

58. Scher B, Seitz M, Albinger W, et al. Value of PET and PET/CT in the diagnostics of prostate and penile cancer. Recent Results Cancer Res 2008;170:159-179. Available at: <http://www.ncbi.nlm.nih.gov/pubmed/18019625>.

59. Scher B, Seitz M, Reiser M, et al. 18F-FDG PET/CT for staging of penile cancer. J Nucl Med 2005;46:1460-1465. Available at: <http://www.ncbi.nlm.nih.gov/pubmed/16157528>.

60. Tabatabaei S, Harisinghani M, McDougal WS. Regional lymph node staging using lymphotropic nanoparticle enhanced magnetic resonance imaging with ferumoxtran-10 in patients with penile cancer. J Urol 2005;174:923-927. Available at: <http://www.ncbi.nlm.nih.gov/pubmed/16093989>.

61. Caso JR, Rodriguez AR, Correa J, Spiess PE. Update in the management of penile cancer. Int Braz J Urol 2009;35:406-415. Available at: <http://www.ncbi.nlm.nih.gov/pubmed/19719855>.

62. Pizzocaro G, Piva L, Bandieramonte G, Tana S. Up-to-date management of carcinoma of the penis. Eur Urol 1997;32:5-15. Available at: <http://www.ncbi.nlm.nih.gov/pubmed/9266225>.

63. Solsona E, Iborra I, Rubio J, et al. Prospective validation of the association of local tumor stage and grade as a predictive factor for occult lymph node micrometastasis in patients with penile carcinoma and clinically negative inguinal lymph nodes. J Urol 2001;165:1506-1509. Available at: <http://www.ncbi.nlm.nih.gov/pubmed/11342906>.

64. Villavicencio H, Rubio-Briones J, Regalado R, et al. Grade, local stage and growth pattern as prognostic factors in carcinoma of the penis. Eur Urol 1997;32:442-447. Available at: <http://www.ncbi.nlm.nih.gov/pubmed/9412803>.

65. Li ZS, Yao K, Chen P, et al. Disease-specific survival after radical lymphadenectomy for penile cancer: prediction by lymph node count and density. *Urol Oncol* 2014;32:893-900. Available at: <http://www.ncbi.nlm.nih.gov/pubmed/24994488>.
66. Cabanas RM. An approach for the treatment of penile carcinoma. *Cancer* 1977;39:456-466. Available at: <http://www.ncbi.nlm.nih.gov/pubmed/837331>.
67. Pettaway CA, Pisters LL, Dinney CP, et al. Sentinel lymph node dissection for penile carcinoma: the M. D. Anderson Cancer Center experience. *J Urol* 1995;154:1999-2003. Available at: <http://www.ncbi.nlm.nih.gov/pubmed/7500444>.
68. Leijte JAP, Kroon BK, Valdes Olmos RA, et al. Reliability and safety of current dynamic sentinel node biopsy for penile carcinoma. *Eur Urol* 2007;52:170-177. Available at: <http://www.ncbi.nlm.nih.gov/pubmed/17316967>.
69. Valdes Olmos RA, Tanis PJ, Hoefnagel CA, et al. Penile lymphoscintigraphy for sentinel node identification. *Eur J Nucl Med* 2001;28:581-585. Available at: <http://www.ncbi.nlm.nih.gov/pubmed/11383862>.
70. Gonzaga-Silva LF, Tavares JM, Freitas FC, et al. The isolated gamma probe technique for sentinel node penile carcinoma detection is unreliable. *Int Braz J Urol* 2007;33:58-63. Available at: <http://www.ncbi.nlm.nih.gov/pubmed/17335599>.
71. Kroon BK, Horenblas S, Meinhardt W, et al. Dynamic sentinel node biopsy in penile carcinoma: evaluation of 10 years experience. *Eur Urol* 2005;47:601-606. Available at: <http://www.ncbi.nlm.nih.gov/pubmed/15826750>.
72. Spiess PE, Izawa JI, Bassett R, et al. Preoperative lymphoscintigraphy and dynamic sentinel node biopsy for staging penile cancer: results with pathological correlation. *J Urol* 2007;177:2157-2161. Available at: <http://www.ncbi.nlm.nih.gov/pubmed/17509308>.
73. Tanis PJ, Lont AP, Meinhardt W, et al. Dynamic sentinel node biopsy for penile cancer: reliability of a staging technique. *J Urol* 2002;168:76-80. Available at: <http://www.ncbi.nlm.nih.gov/pubmed/12050496>.
74. Kroon BK, Horenblas S, Estourgie SH, et al. How to avoid false-negative dynamic sentinel node procedures in penile carcinoma. *J Urol* 2004;171:2191-2194. Available at: <http://www.ncbi.nlm.nih.gov/pubmed/15126783>.
75. Kroon BK, Horenblas S, Deurloo EE, et al. Ultrasonography-guided fine-needle aspiration cytology before sentinel node biopsy in patients with penile carcinoma. *BJU Int* 2005;95:517-521. Available at: <http://www.ncbi.nlm.nih.gov/pubmed/15705071>.
76. Crawshaw JW, Hadway P, Hoffland D, et al. Sentinel lymph node biopsy using dynamic lymphoscintigraphy combined with ultrasound-guided fine needle aspiration in penile carcinoma. *Br J Radiol* 2009;82:41-48. Available at: <http://www.ncbi.nlm.nih.gov/pubmed/19095815>.
77. Hadway P, Smith Y, Corbishley C, et al. Evaluation of dynamic lymphoscintigraphy and sentinel lymph-node biopsy for detecting occult metastases in patients with penile squamous cell carcinoma. *BJU Int* 2007;100:561-565. Available at: <http://www.ncbi.nlm.nih.gov/pubmed/17578518>.
78. Djajadiningrat RS, Graafland NM, van Werkhoven E, et al. Contemporary management of regional nodes in penile cancer—improvement of survival? *J Urol* 2014;191:68-73. Available at:
79. Ficarra V, Galfano A. Should the dynamic sentinel node biopsy (DSNB) be considered the gold standard in the evaluation of lymph node status in patients with penile carcinoma? *Eur Urol* 2007;52:17-19. Available at: <http://www.ncbi.nlm.nih.gov/pubmed/17376585>.



80. Stancik I, Holtl W. Penile cancer: review of the recent literature. *Curr Opin Urol* 2003;13:467-472. Available at: <http://www.ncbi.nlm.nih.gov/pubmed/14560140>.
81. Kroon BK, Horenblas S, Lont AP, et al. Patients with penile carcinoma benefit from immediate resection of clinically occult lymph node metastases. *J Urol* 2005;173:816-819. Available at: <http://www.ncbi.nlm.nih.gov/pubmed/15711276>.
82. McDougal WS. Preemptive lymphadenectomy markedly improves survival in patients with cancer of the penis who harbor occult metastases. *J Urol* 2005;173:681. Available at: <http://www.ncbi.nlm.nih.gov/pubmed/15711242>.
83. Sharp DS, Angermeier KW. Surgery of penile and urethral carcinoma. In: Wein AJ, Kavoussi L, Novick AC, et al., eds. *Campbell-Walsh Urology* (ed 9). Philadelphia: Saunders; 2007:993-1022.
84. Spiess PE, Hernandez MS, Pettaway CA. Contemporary inguinal lymph node dissection: minimizing complications. *World J Urol* 2009;27:205-212. Available at: <http://www.ncbi.nlm.nih.gov/pubmed/18762945>.
85. Catalona WJ. Re: Modified inguinal lymphadenectomy for carcinoma of the penis with preservation of saphenous veins: technique and preliminary results. *J Urol* 1988;140:836-836. Available at: <http://www.ncbi.nlm.nih.gov/pubmed/3418818>.
86. Lopes A, Rossi BM, Fonseca FP, Morini S. Unreliability of modified inguinal lymphadenectomy for clinical staging of penile carcinoma. *Cancer* 1996;77:2099-2102. Available at: <http://www.ncbi.nlm.nih.gov/pubmed/8640676>.
87. Protzel C, Alcaraz A, Horenblas S, et al. Lymphadenectomy in the surgical management of penile cancer. *Eur Urol* 2009;55:1075-1088. Available at: <http://www.ncbi.nlm.nih.gov/pubmed/19264390>.
88. Bermejo C, Busby JE, Spiess PE, et al. Neoadjuvant chemotherapy followed by aggressive surgical consolidation for metastatic penile squamous cell carcinoma. *J Urol* 2007;177:1335-1338. Available at: <http://www.ncbi.nlm.nih.gov/pubmed/17382727>.
89. Pagliaro LC, Crook J. Multimodality therapy in penile cancer: when and which treatments? *World J Urol* 2009;27:221-225. Available at: <http://www.ncbi.nlm.nih.gov/pubmed/18682961>.
90. Soria JC, Fizazi K, Piron D, et al. Squamous cell carcinoma of the penis: multivariate analysis of prognostic factors and natural history in monocentric study with a conservative policy. *Ann Oncol* 1997;8:1089-1098. Available at: <http://www.ncbi.nlm.nih.gov/pubmed/9426328>.
91. Theodorescu D, Russo P, Zhang ZF, et al. Outcomes of initial surveillance of invasive squamous cell carcinoma of the penis and negative nodes. *J Urol* 1996;155:1626-1631. Available at: <http://www.ncbi.nlm.nih.gov/pubmed/8627839>.
92. Leijte JAP, Kirrander P, Antonini N, et al. Recurrence patterns of squamous cell carcinoma of the penis: recommendations for follow-up based on a two-centre analysis of 700 patients. *Eur Urol* 2008;54:161-168. Available at: <http://www.ncbi.nlm.nih.gov/pubmed/18440124>.
93. Grabstald H. Controversies concerning lymph node dissection for cancer of the penis. *Urol Clin North Am* 1980;7:793-799. Available at: <http://www.ncbi.nlm.nih.gov/pubmed/7456188>.
94. Horenblas S, van Tinteren H, Delemarre JF, et al. Squamous cell carcinoma of the penis. III. Treatment of regional lymph nodes. *J Urol* 1993;149:492-497. Available at: <http://www.ncbi.nlm.nih.gov/pubmed/8437253>.
95. Lughezzani G, Catanzaro M, Torelli T, et al. The relationship between characteristics of inguinal lymph nodes and pelvic lymph node involvement in penile squamous cell carcinoma: a single institution experience. *J Urol* 2014;191:977-982. Available at: <http://www.ncbi.nlm.nih.gov/pubmed/24262497>.

96. Lont AP, Kroon BK, Gallee MP, et al. Pelvic lymph node dissection for penile carcinoma: extent of inguinal lymph node involvement as an indicator for pelvic lymph node involvement and survival. *J Urol* 2007;177:947-952; discussion 952. Available at: <http://www.ncbi.nlm.nih.gov/pubmed/17296384>.
97. Pagliaro LC, Williams DL, Daliani D, et al. Neoadjuvant paclitaxel, ifosfamide, and cisplatin chemotherapy for metastatic penile cancer: a phase II study. *J Clin Oncol* 2010;28:3851-3857. Available at: <http://www.ncbi.nlm.nih.gov/pubmed/20625118>.
98. Leijte JAP, Hughes B, Graafland NM, et al. Two-center evaluation of dynamic sentinel node biopsy for squamous cell carcinoma of the penis. *J Clin Oncol* 2009;27:3325-3329. Available at: <http://www.ncbi.nlm.nih.gov/pubmed/19414668>.
99. Lont AP, Horenblas S, Tanis PJ, et al. Management of clinically node negative penile carcinoma: improved survival after the introduction of dynamic sentinel node biopsy. *J Urol* 2003;170:783-786. Available at: <http://www.ncbi.nlm.nih.gov/pubmed/12913697>.
100. Chaux A, Reuter V, Lezcano C, et al. Comparison of morphologic features and outcome of resected recurrent and nonrecurrent squamous cell carcinoma of the penis: a study of 81 cases. *Am J Surg Pathol* 2009;33:1299-1306. Available at: <http://www.ncbi.nlm.nih.gov/pubmed/19471153>.
101. Ornellas AA, Nobrega BL, Wei Kin Chin E, et al. Prognostic factors in invasive squamous cell carcinoma of the penis: analysis of 196 patients treated at the Brazilian National Cancer Institute. *J Urol* 2008;180:1354-1359. Available at: <http://www.ncbi.nlm.nih.gov/pubmed/18707720>.
102. Graafland NM, Moonen LM, van Boven HH, et al. Inguinal recurrence following therapeutic lymphadenectomy for node positive penile carcinoma: outcome and implications for management. *J Urol* 2011;185:888-893. Available at: <http://www.ncbi.nlm.nih.gov/pubmed/21239009>.
103. Baumgarten AS, Alhammali E, Hakky TS, et al. Salvage surgical resection for isolated locally recurrent inguinal lymph node metastasis of penile cancer: international study collaboration. *J Urol* 2014;192:760-764. Available at: <http://www.ncbi.nlm.nih.gov/pubmed/24603104>.
104. Lopes A, Bezerra AL, Serrano SV, Hidalgo GS. Iliac nodal metastases from carcinoma of the penis treated surgically. *BJU Int* 2000;86:690-693. Available at: <http://www.ncbi.nlm.nih.gov/pubmed/11069378>.
105. Pow-Sang JE, Benavente V, Pow-Sang JM, Pow-Sang M. Bilateral ilioinguinal lymph node dissection in the management of cancer of the penis. *Semin Surg Oncol* 1990;6:241-242. Available at: <http://www.ncbi.nlm.nih.gov/pubmed/2389105>.
106. Ravi R. Morbidity following groin dissection for penile carcinoma. *Br J Urol* 1993;72:941-945. Available at: <http://www.ncbi.nlm.nih.gov/pubmed/8306161>.
107. Sanchez-Ortiz RF, Pettaway CA. The role of lymphadenectomy in penile cancer. *Urol Oncol* 2004;22:236-244. Available at: <http://www.ncbi.nlm.nih.gov/pubmed/15271324>.
108. Srinivas V, Morse MJ, Herr HW, et al. Penile cancer: relation of extent of nodal metastasis to survival. *J Urol* 1987;137:880-882. Available at: <http://www.ncbi.nlm.nih.gov/pubmed/3573181>.
109. Culkin DJ, Beer TM. Advanced penile carcinoma. *J Urol* 2003;170:359-365. Available at: <http://www.ncbi.nlm.nih.gov/pubmed/12853775>.
110. Pettaway CA, Pagliaro L, Theodore C, Haas G. Treatment of visceral, unresectable, or bulky/unresectable regional metastases of penile cancer. *Urology* 2010;76:58-65. Available at: <http://www.ncbi.nlm.nih.gov/pubmed/20691886>.
111. Di Lorenzo G, Buonerba C, Federico P, et al. Cisplatin and 5-fluorouracil in inoperable, stage IV squamous cell carcinoma of the



NCCN Guidelines Version 1.2016 Penile Cancer

penis. BJU Int 2012;110:E661-666. Available at:
<http://www.ncbi.nlm.nih.gov/pubmed/22958571>.

112. Haas GP, Blumenstein BA, Gagliano RG, et al. Cisplatin, methotrexate and bleomycin for the treatment of carcinoma of the penis: a Southwest Oncology Group study. J Urol 1999;161:1823-1825. Available at: <http://www.ncbi.nlm.nih.gov/pubmed/10332445>.

113. Di Lorenzo G, Federico P, Buonerba C, et al. Paclitaxel in pretreated metastatic penile cancer: final results of a phase 2 study. Eur Urol 2011;60:1280-1284. Available at: <http://www.ncbi.nlm.nih.gov/pubmed/21871710>.

114. Carthon BC, Ng CS, Pettaway CA, Pagliaro LC. Epidermal growth factor receptor-targeted therapy in locally advanced or metastatic squamous cell carcinoma of the penis. BJU Int 2014;113:871-877. Available at: <http://www.ncbi.nlm.nih.gov/pubmed/24053151>.

Discussion
update in
progress